

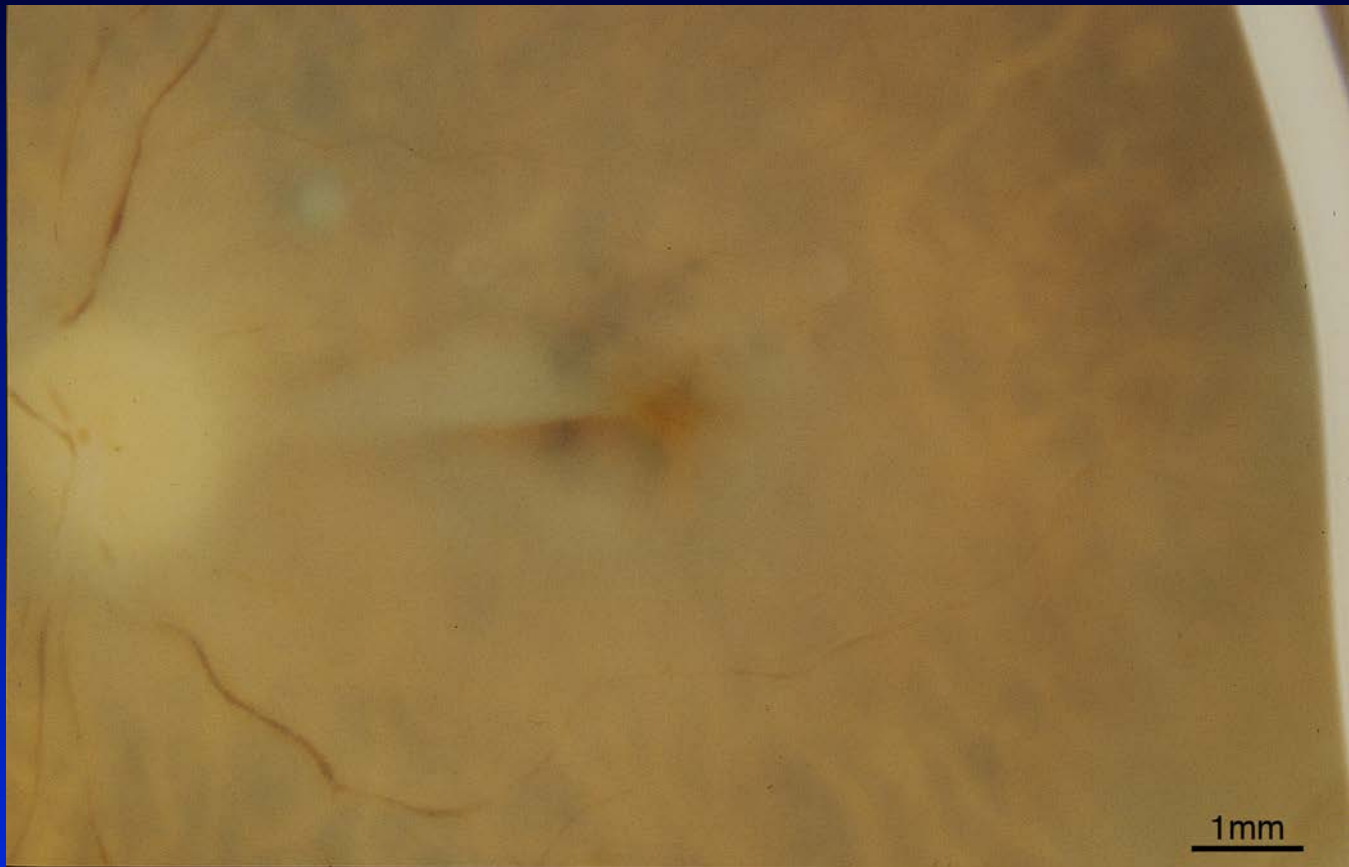
Project MACULA Case Report

2003029L

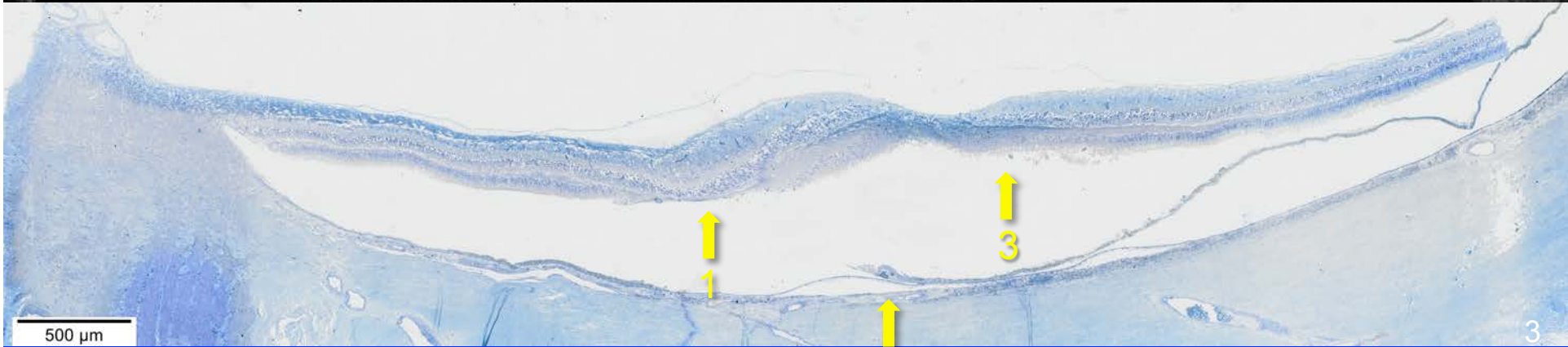
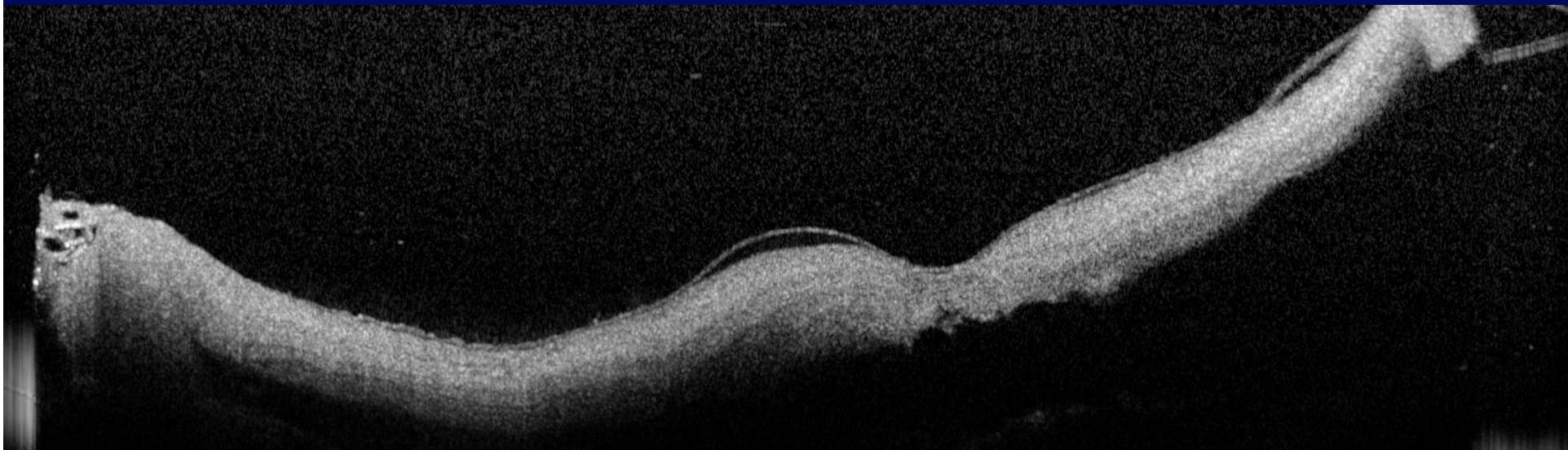
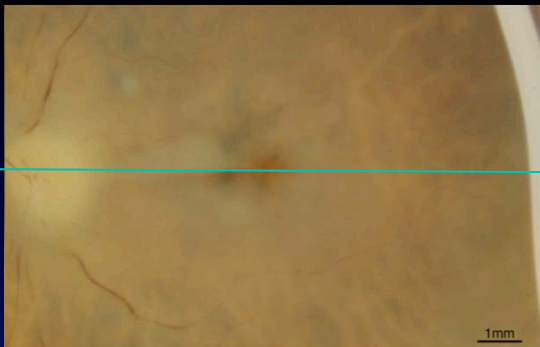
85, Caucasian female

Non-neovascular AMD

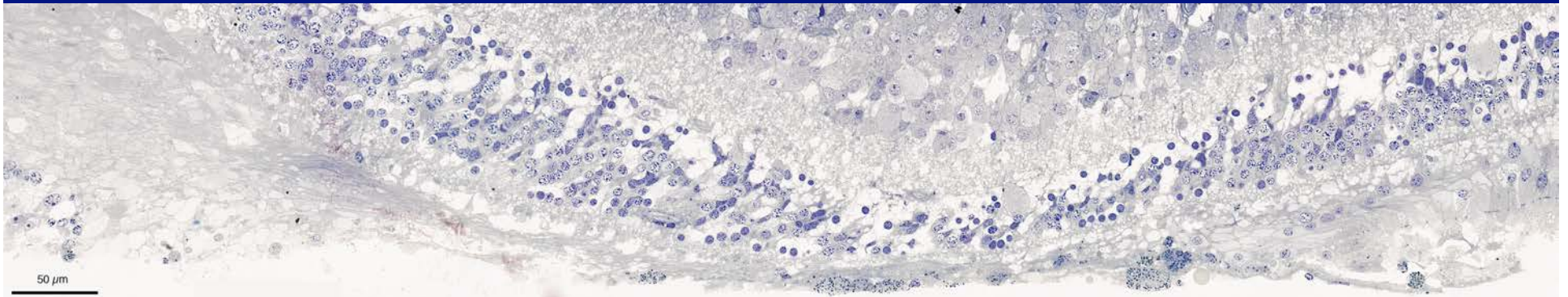
Geographic Atrophy



Foveal sections



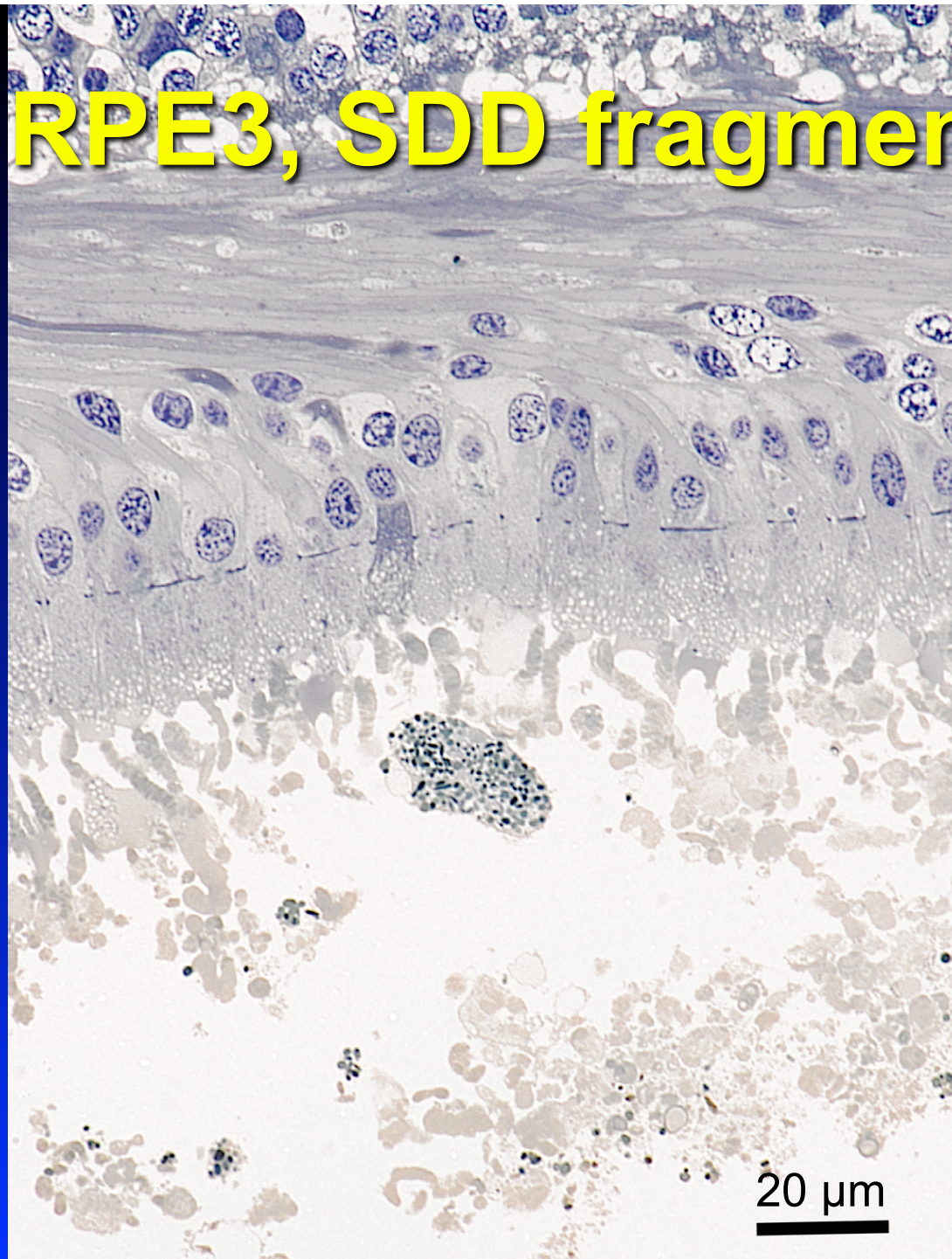
1 GA borders, nasal and temporal



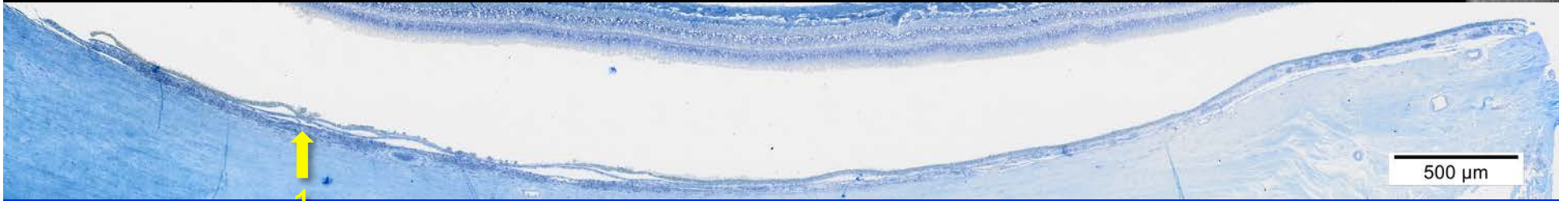
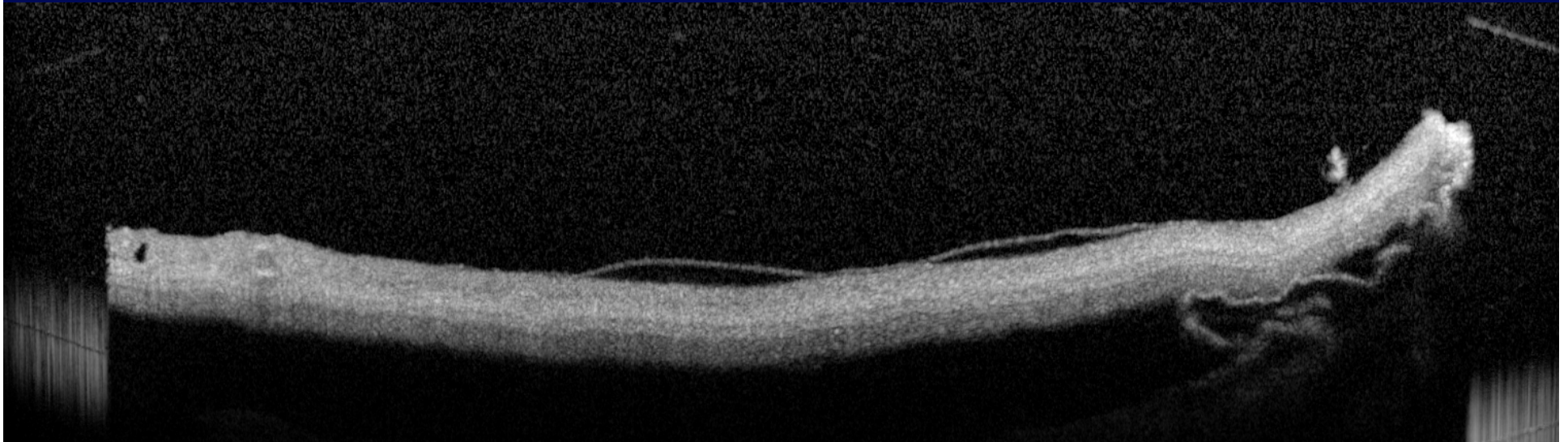
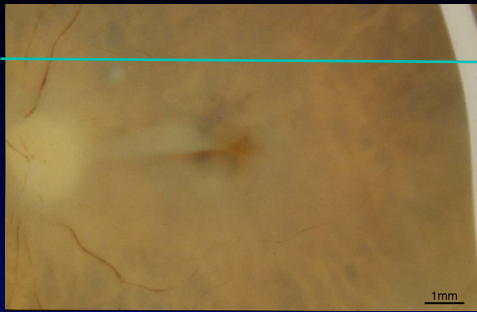
2 RPE-like cells external to BLamD, also RPE2B




3 RPE3, SDD fragments



Perifoveal sections



1 Pigmented cells in sub-RPE space



Project MACULA Case Report

Christine A. Curcio, PhD

curcio@uab.edu

projectmacula.cis.uab.edu



UAB