

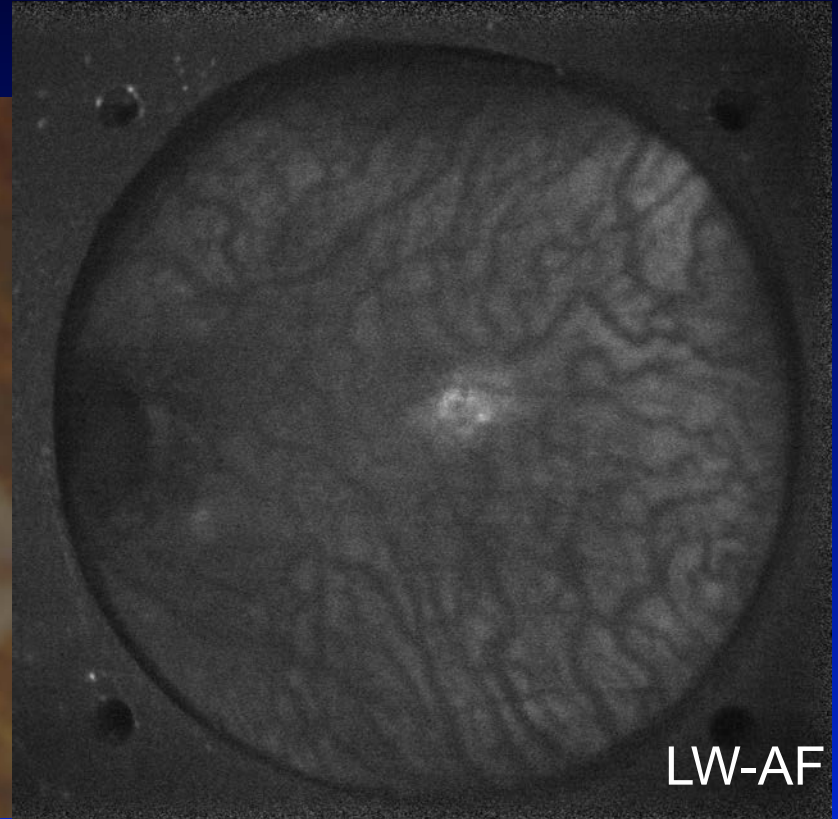
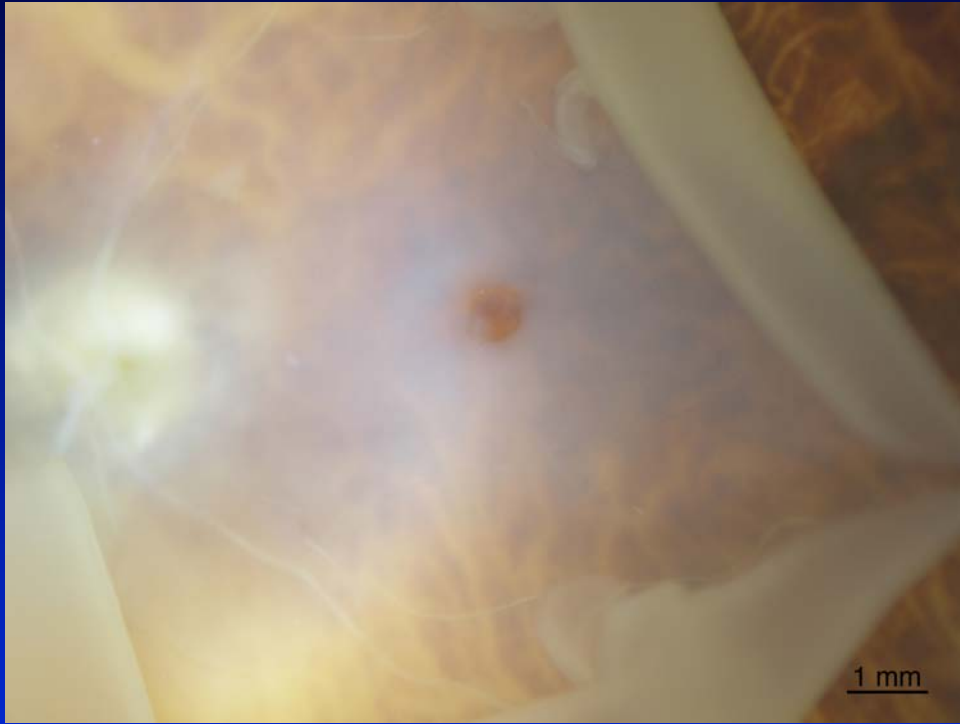Project MACULA Case Report

2003006R


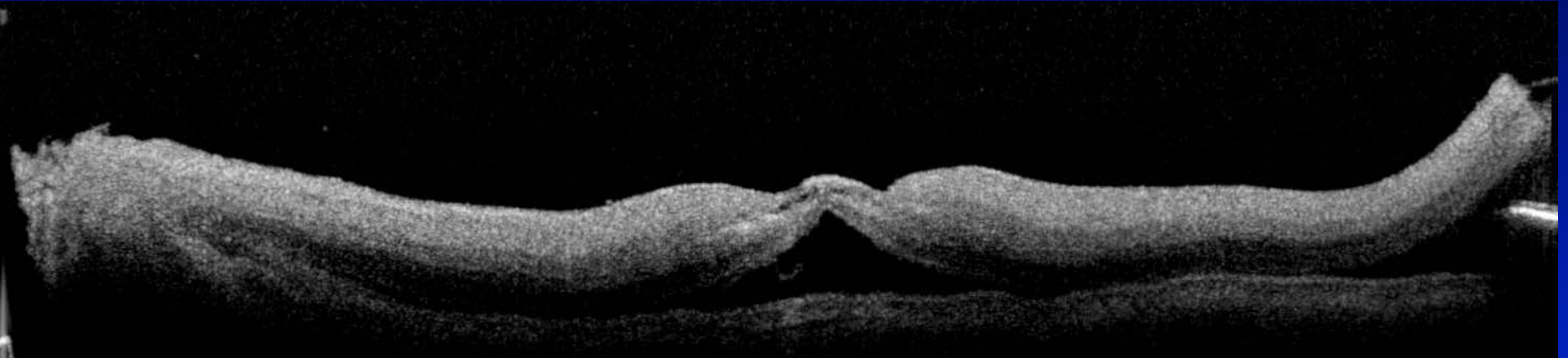

88, Caucasian male

Unremarkable macula

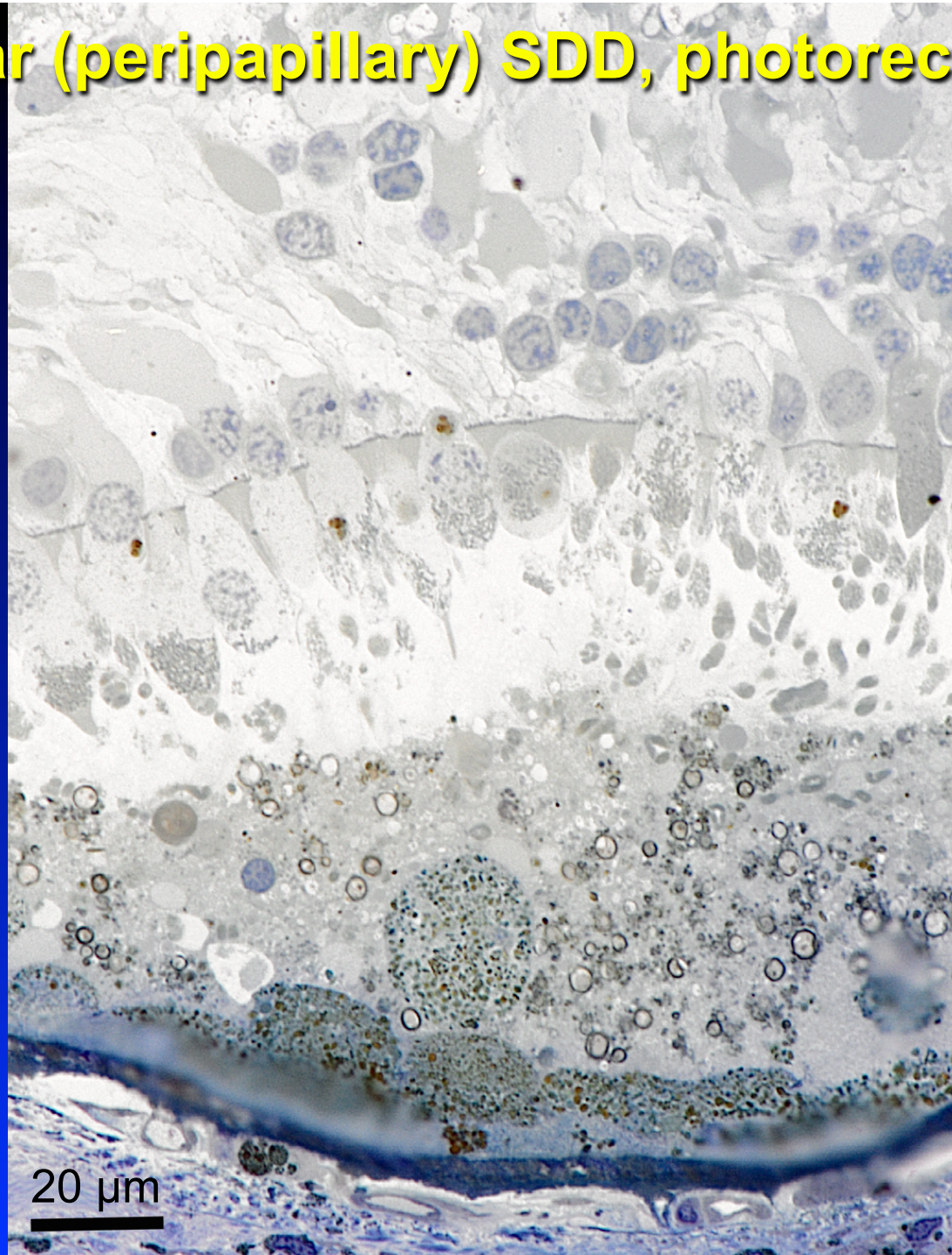
Shown as L



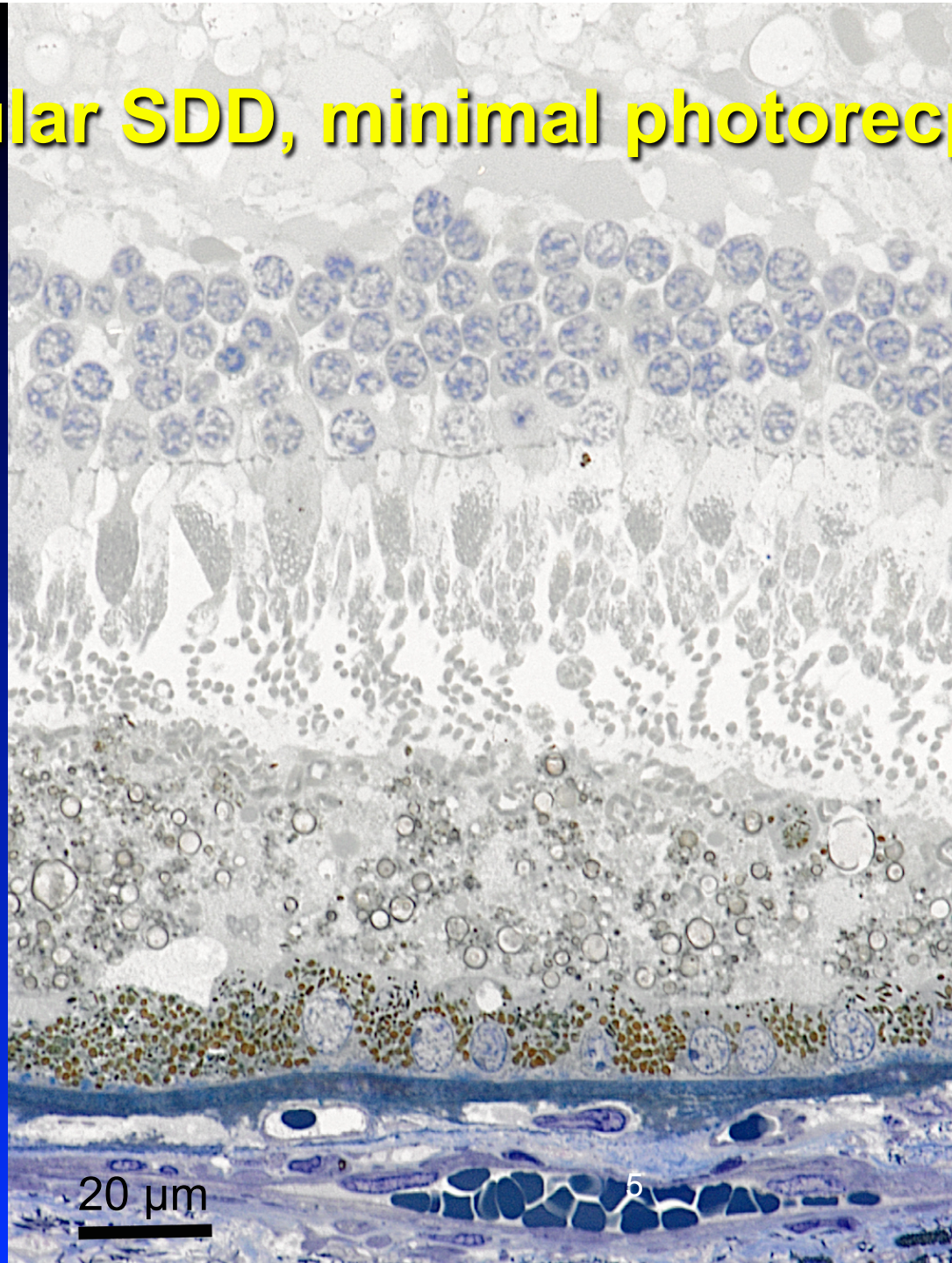
Foveal sections



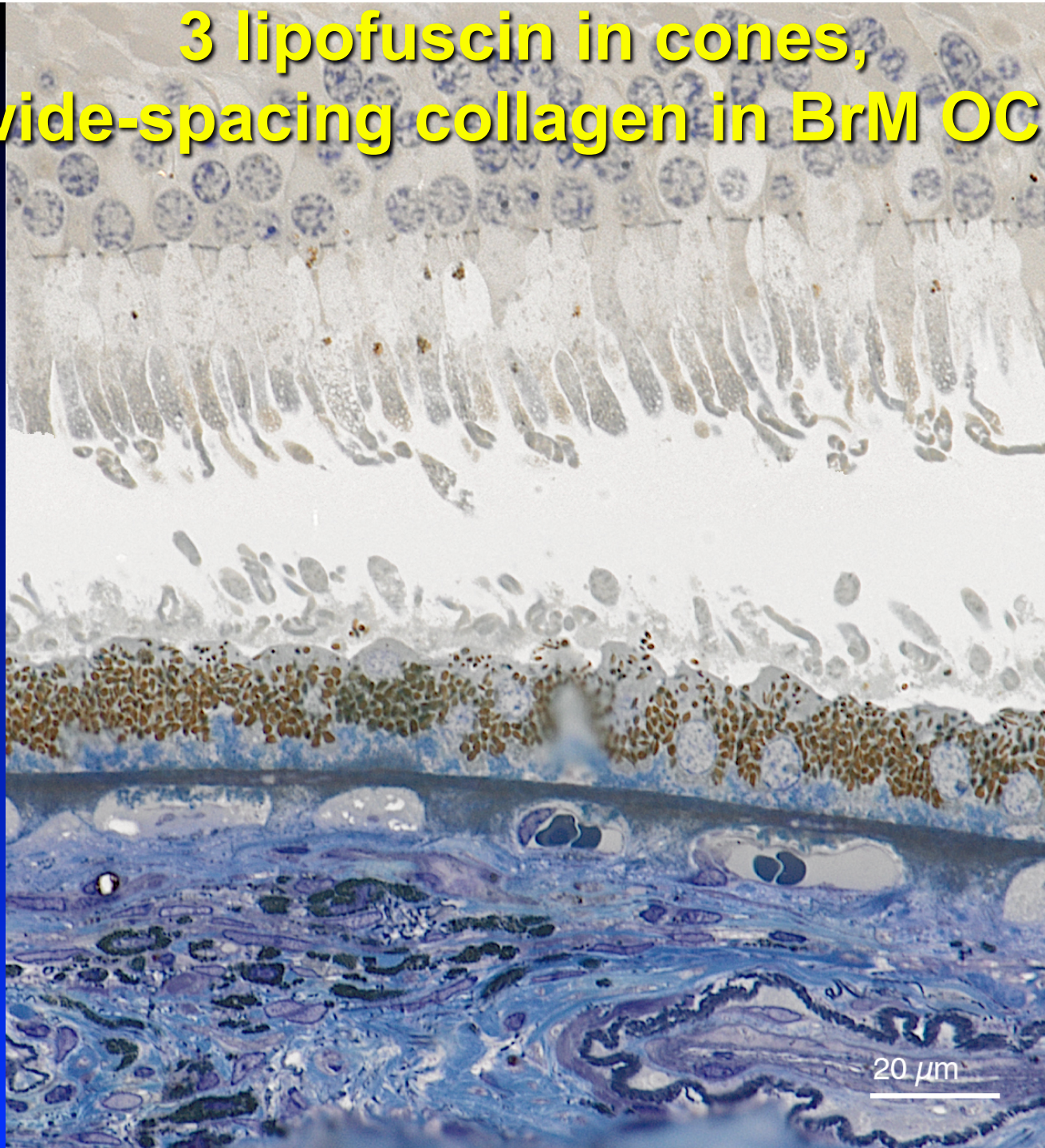
1 vesicular (peripapillary) SDD, photoreceptor loss



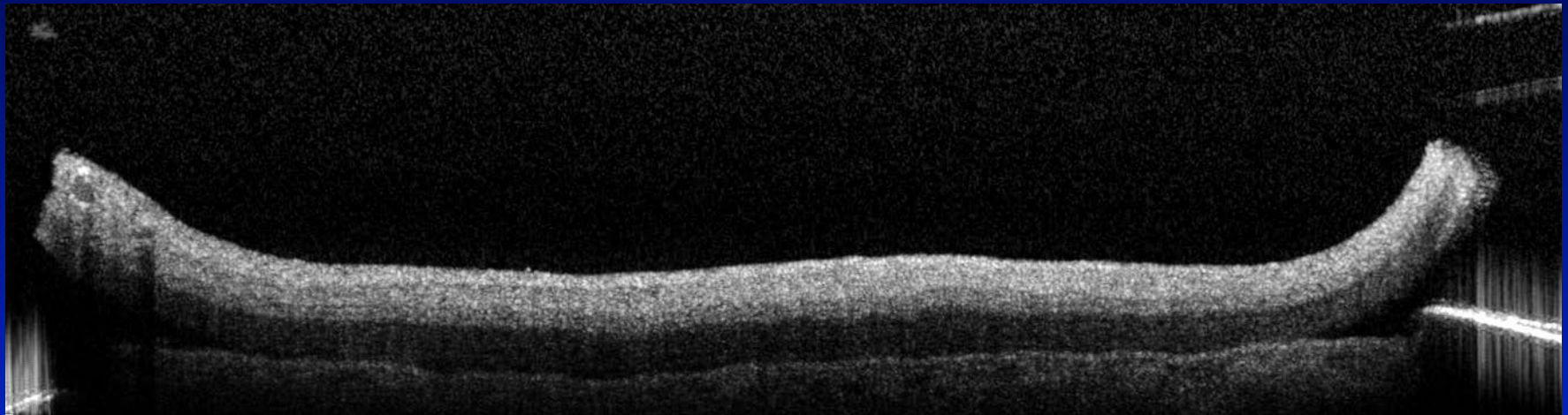
2 vesicular SDD, minimal photoreceptor loss



**3 lipofuscin in cones,
wide-spacing collagen in BrM OCL**



Perifoveal sections



Project MACULA Case Report

Christine A. Curcio, PhD

curcio@uab.edu

projectmacula.cis.uab.edu



UAB