

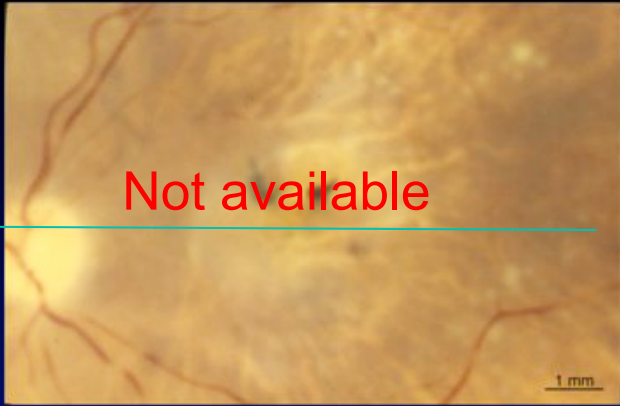
# **Project MACULA Case Report**

0098065R 90F

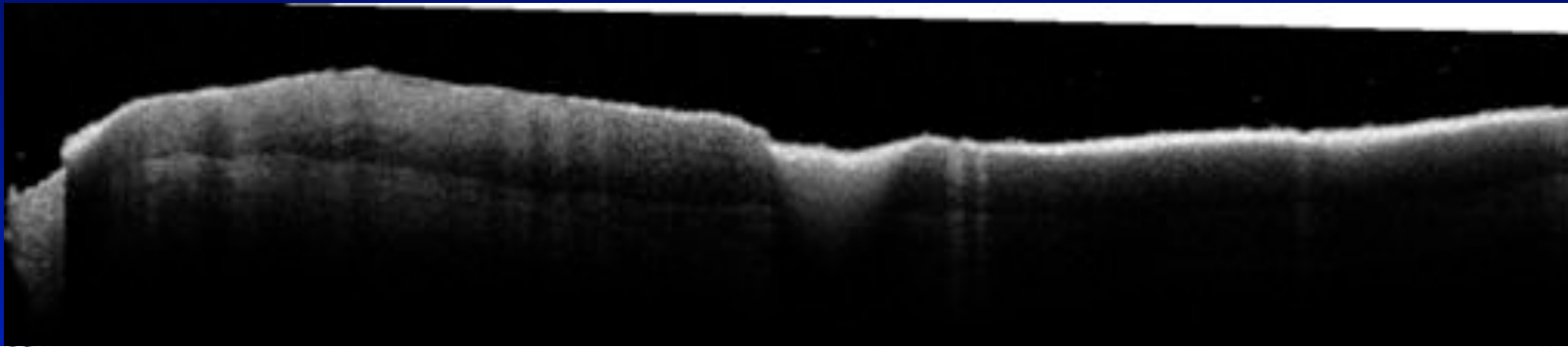
Caucasian female

Neovascular AMD

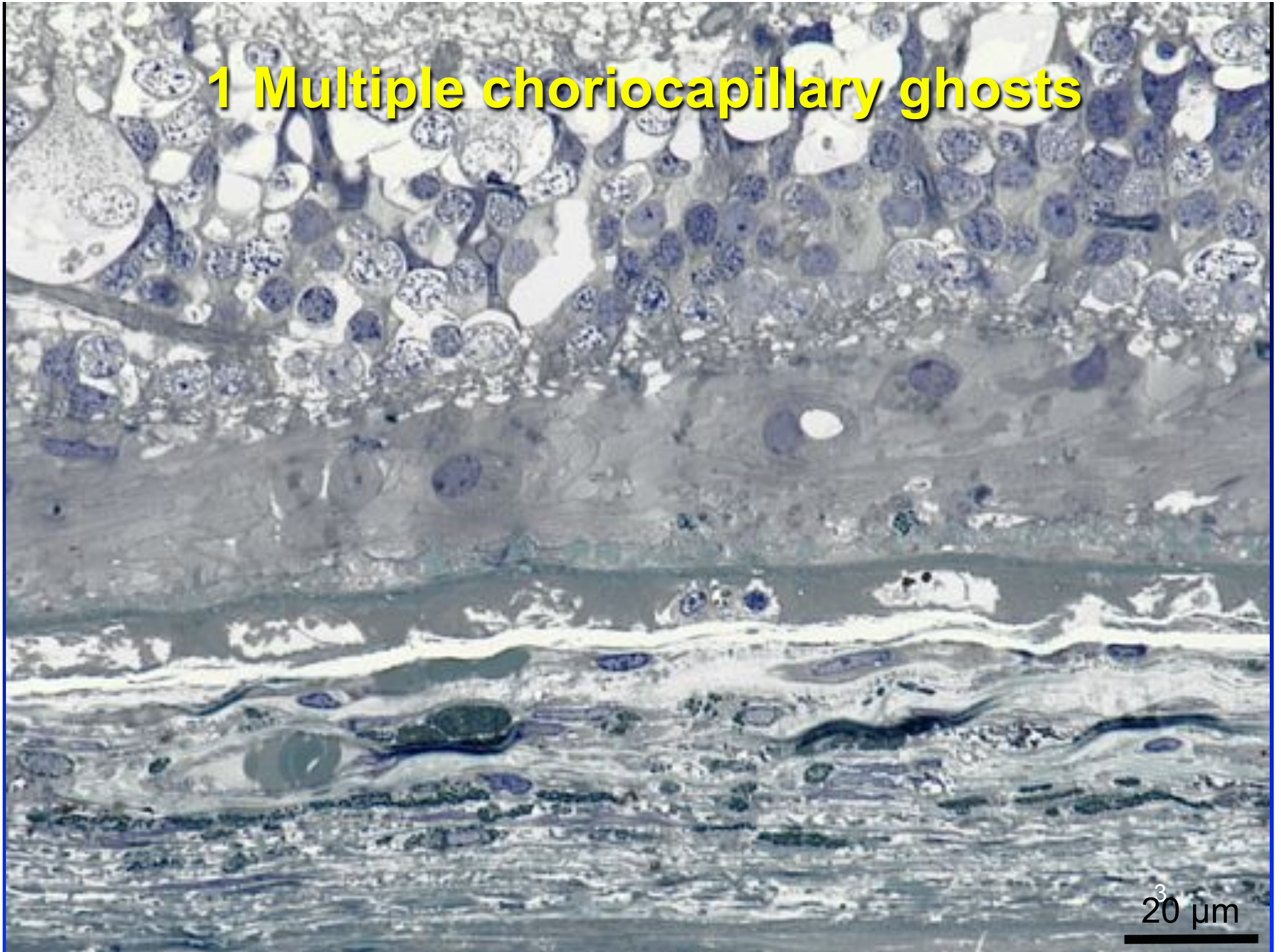Shown as L



# Foveal sections



# 1 Multiple choriocapillary ghosts

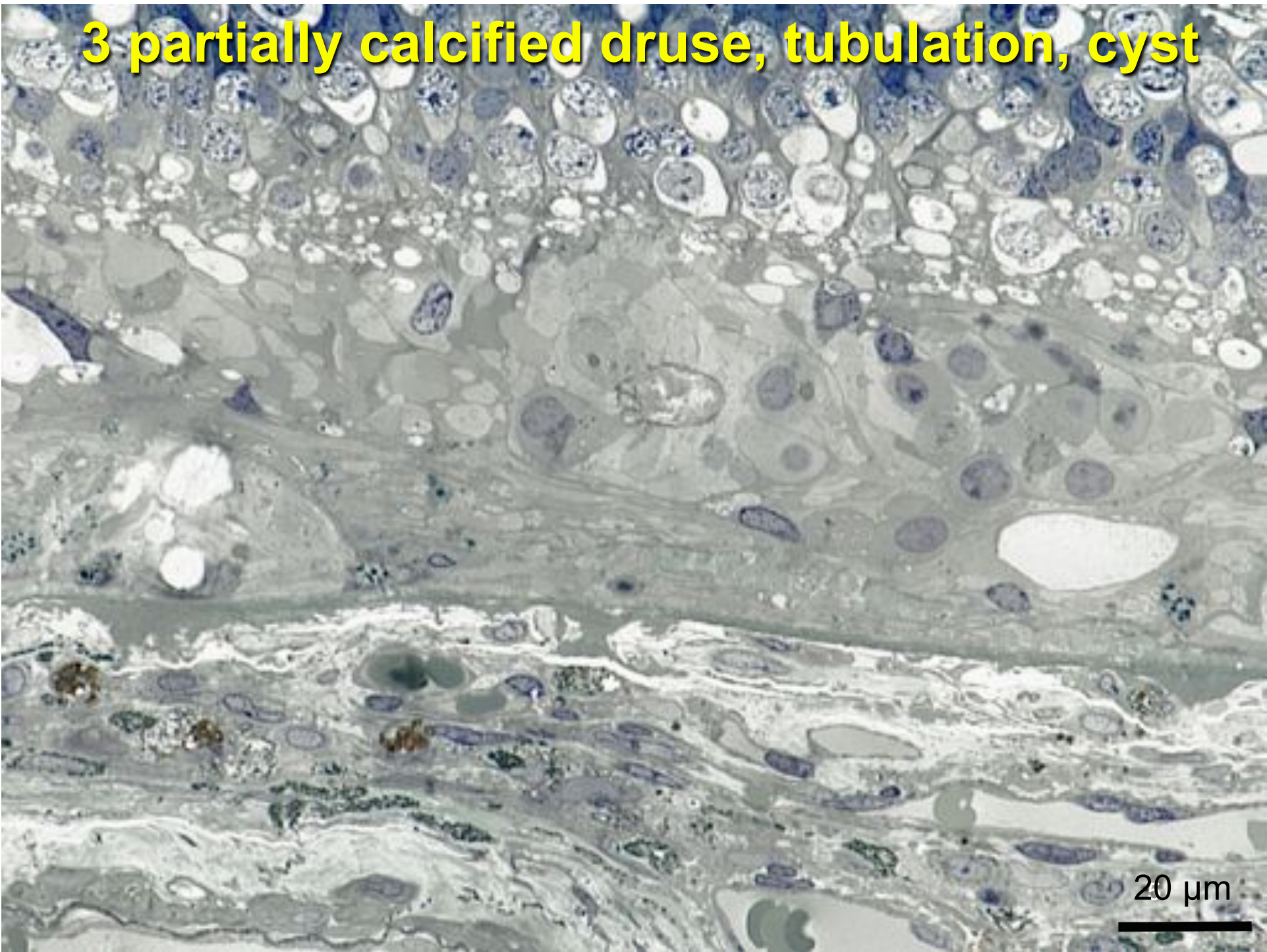


20  $\mu$ m

## 2 Tubulation in foveal center

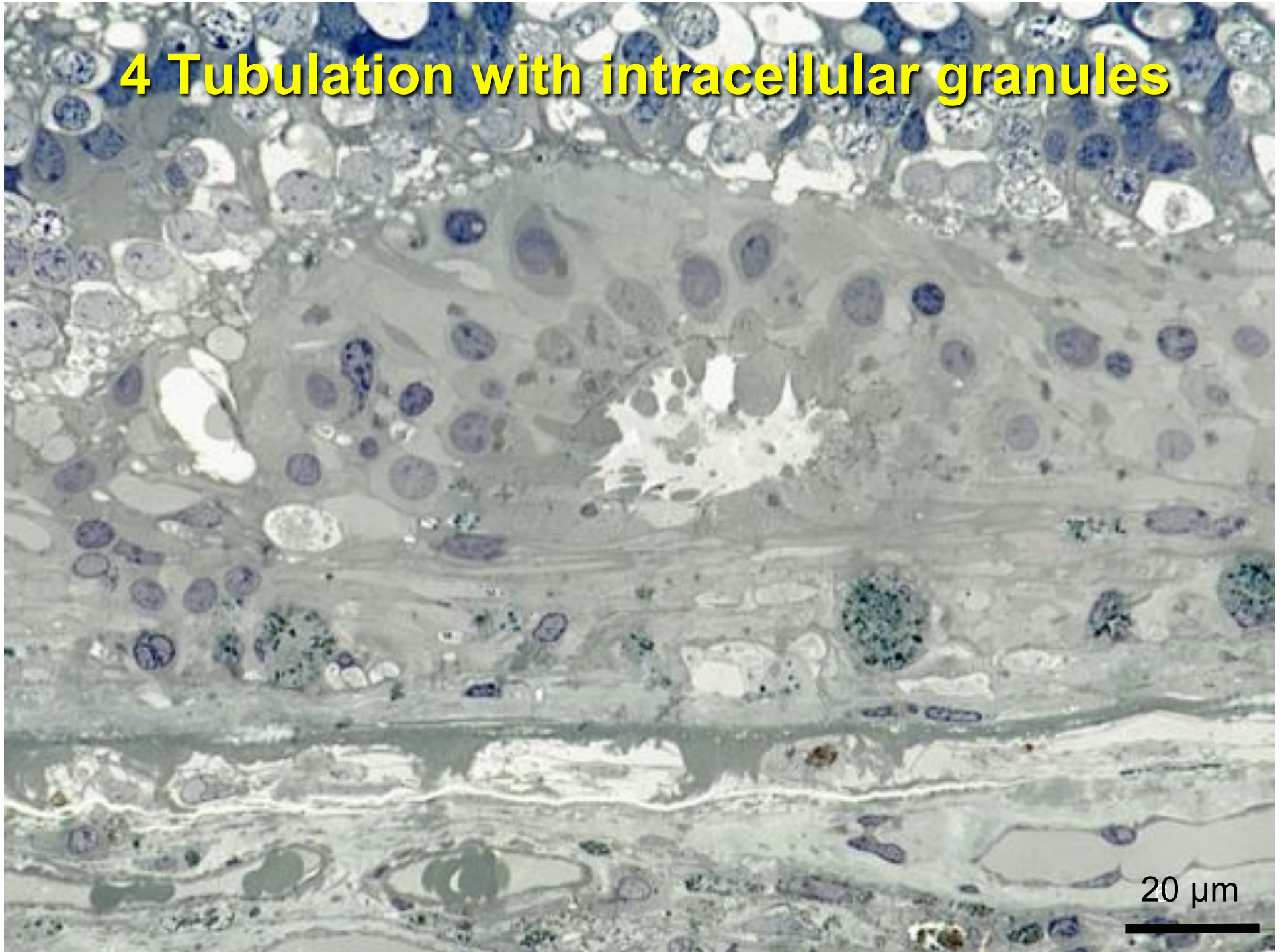


**3 partially calcified druse, tubulation, cyst**



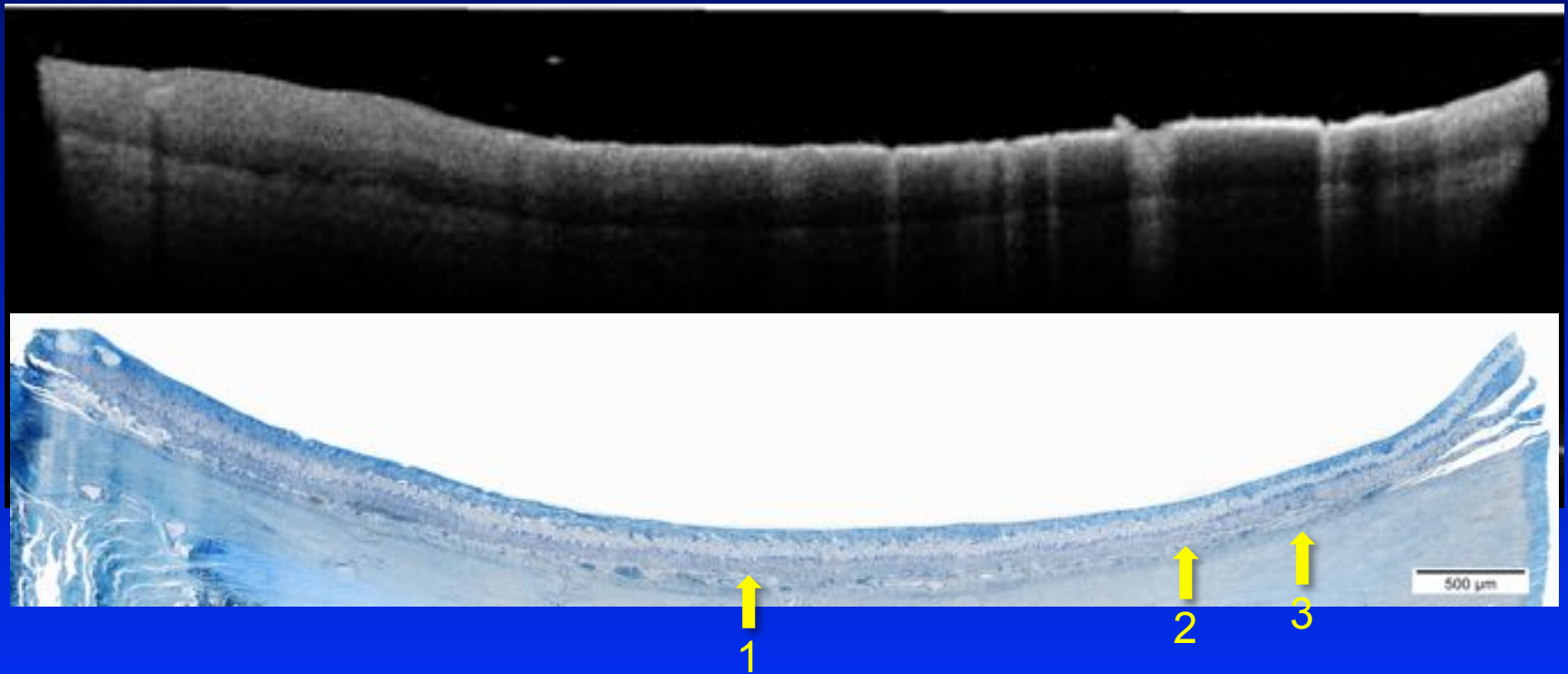
20  $\mu$ m

## 4 Tubulation with intracellular granules

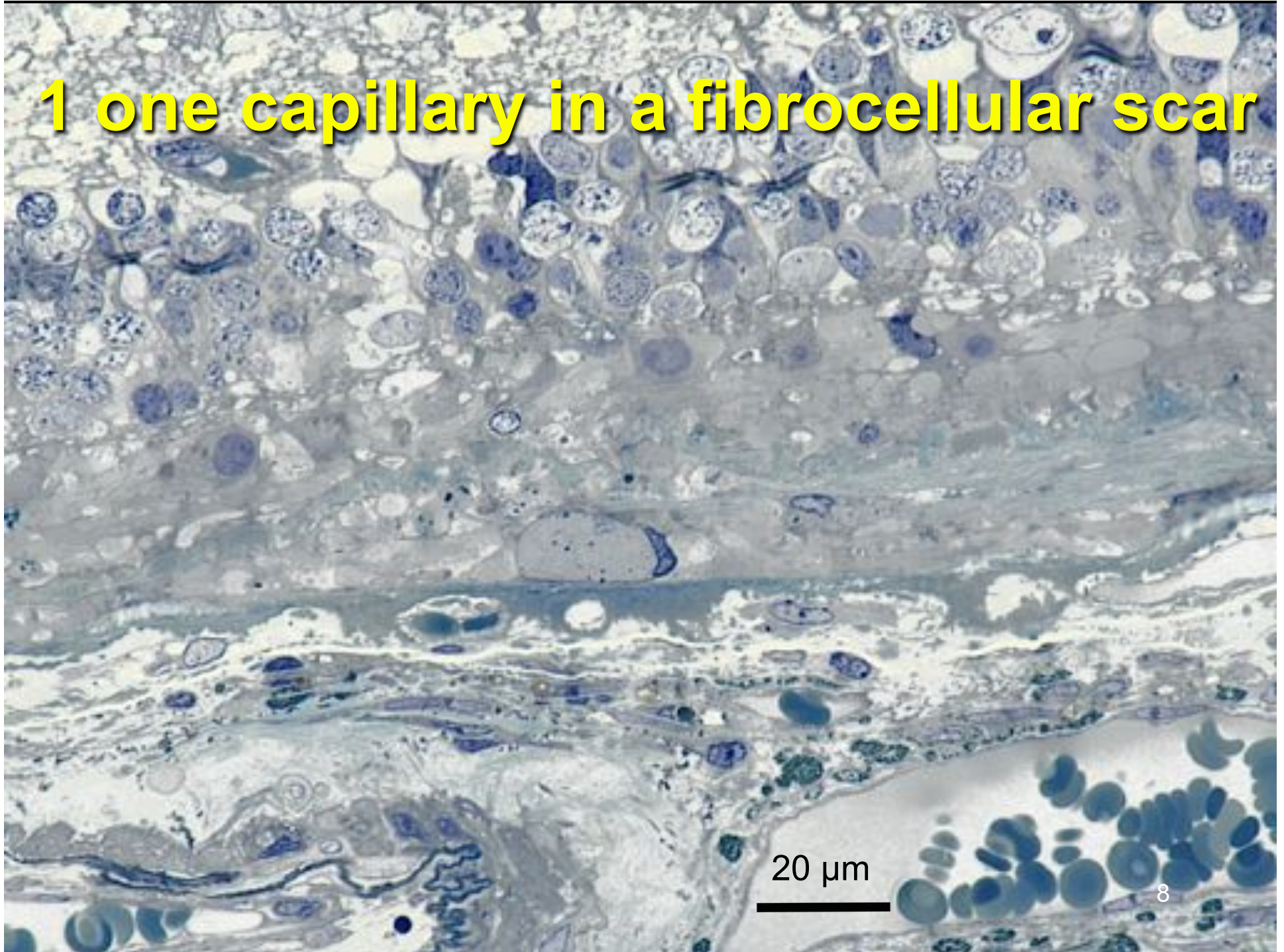



# Perifoveal sections




**1 one capillary in a fibrocellular scar**



20  $\mu$ m



## 2 Two asymmetric tubulations



### 3 Hyalinized choroid with deep capillaries



20  $\mu$ m

10

# Project MACULA Case Report

Christine A. Curcio, PhD

