

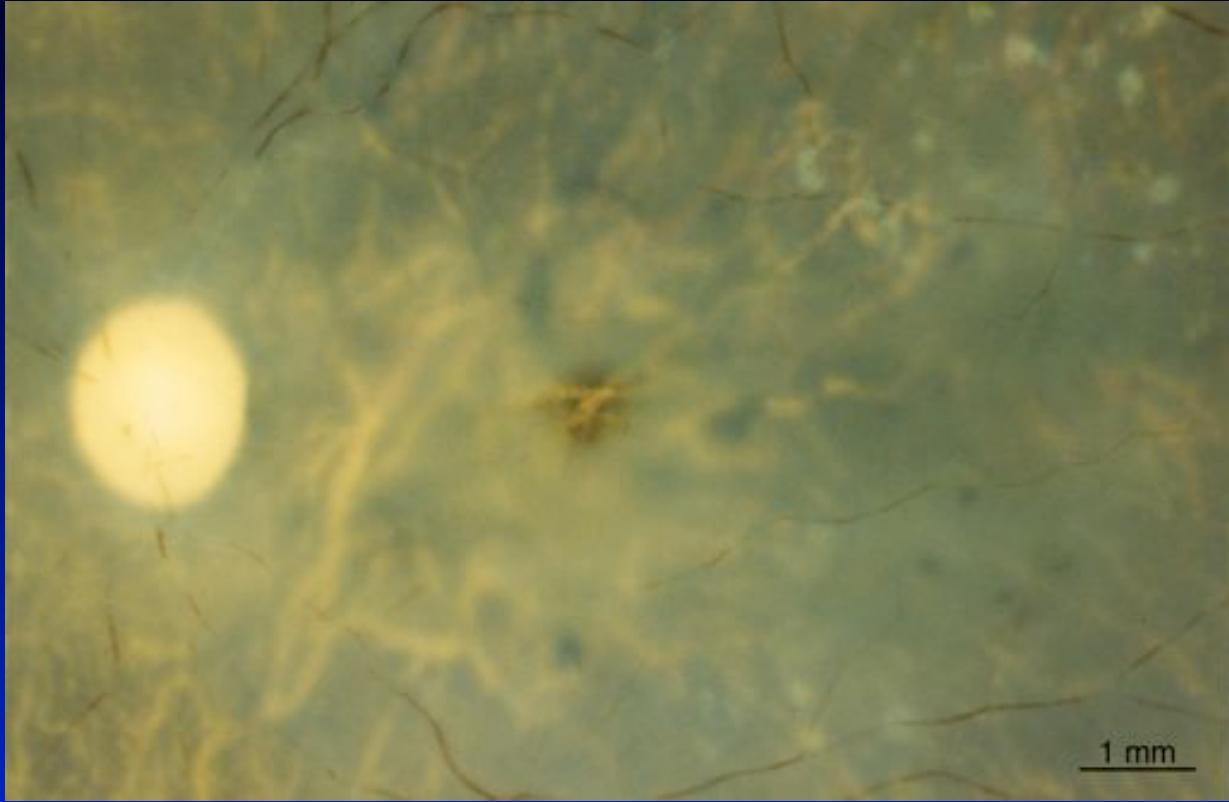# **Project MACULA**

## **Case Report**

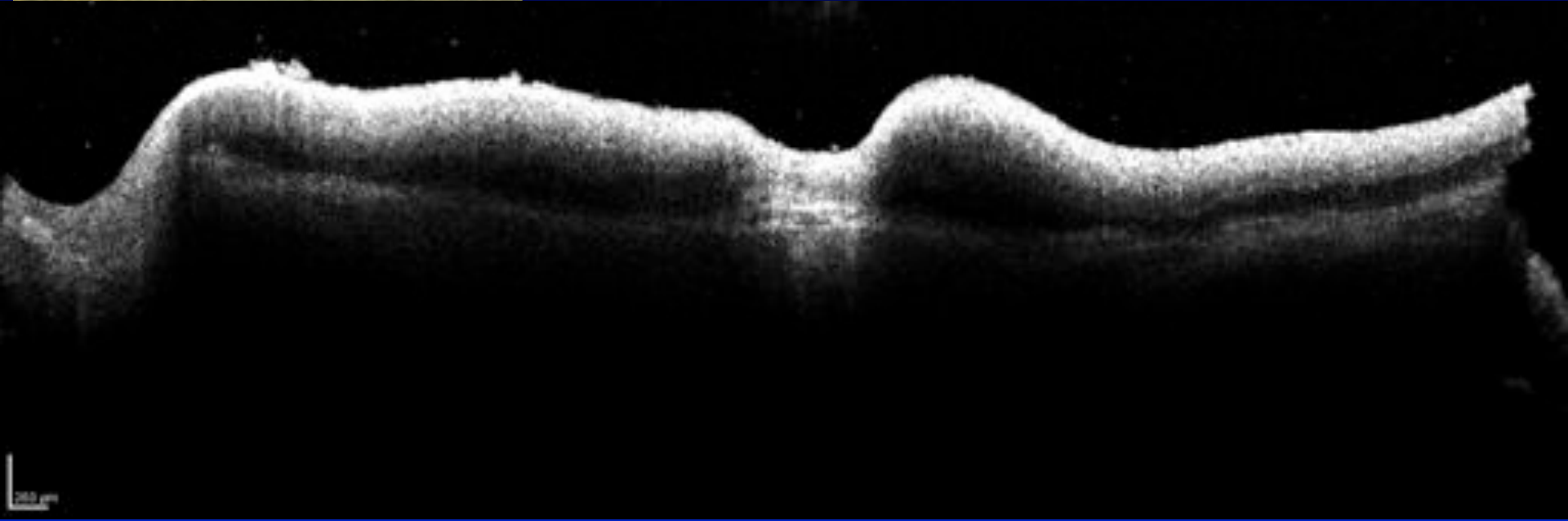
0096047L 94 yr old

Caucasian female

Neovascular AMD



# Foveal sections



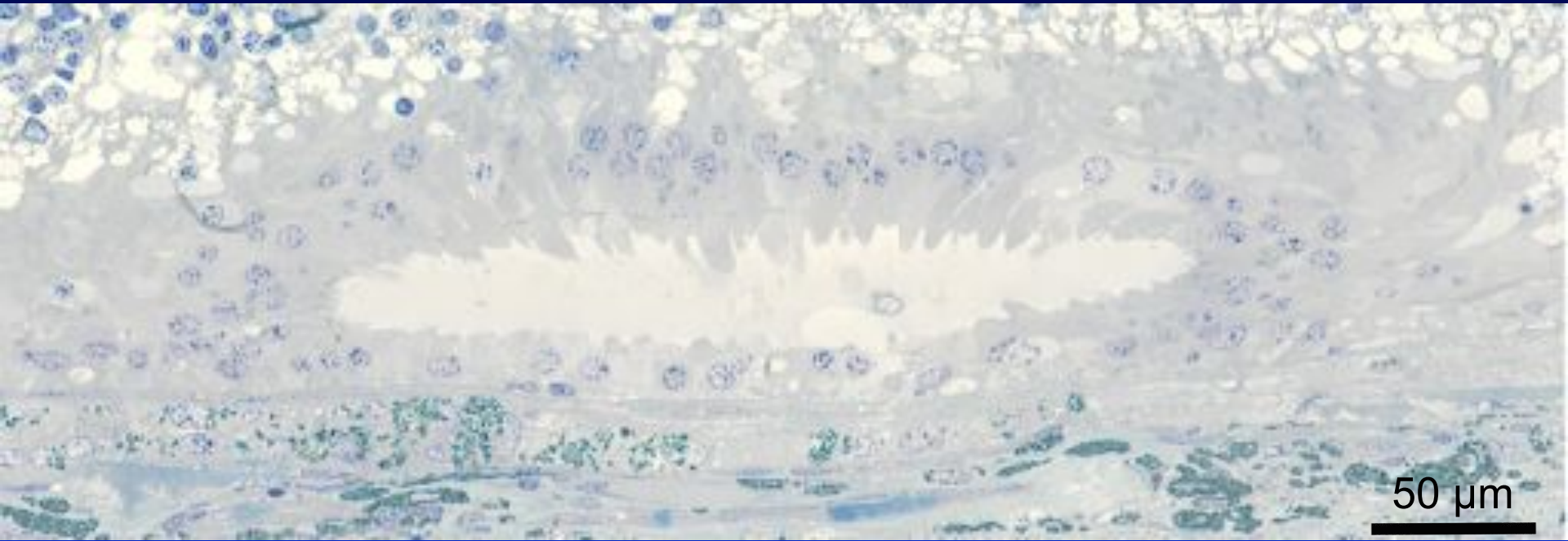
1

2


3

3

# 1 Tubulation, 360°

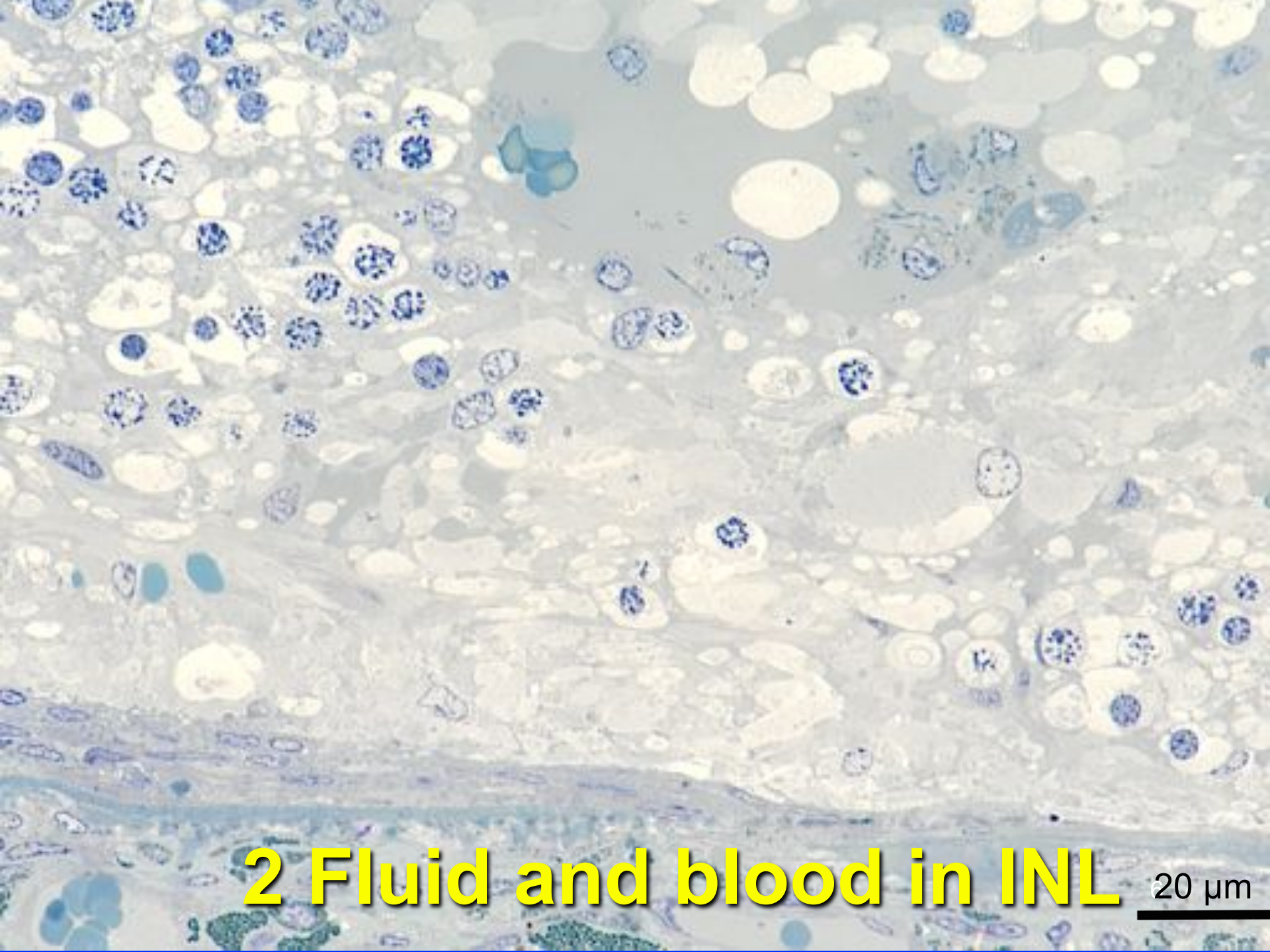


# 2 Active CNV with pericytes



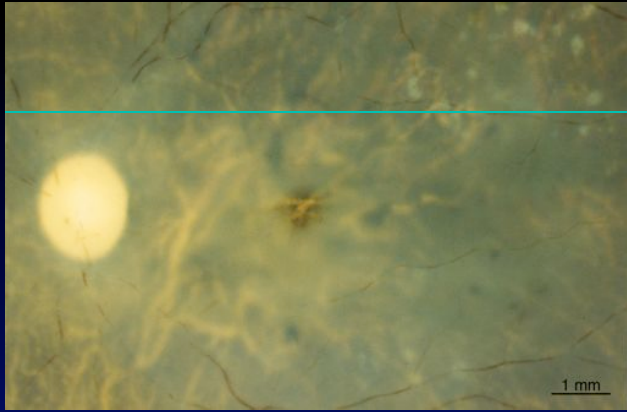
Break in BrM



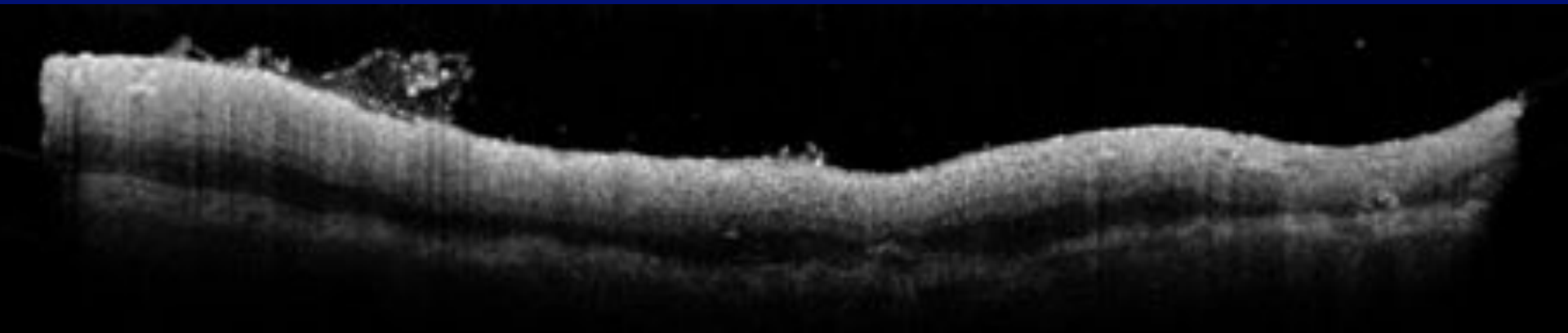


**2 Fluid and blood in INL**

20  $\mu$ m



# Perifoveal sections



5

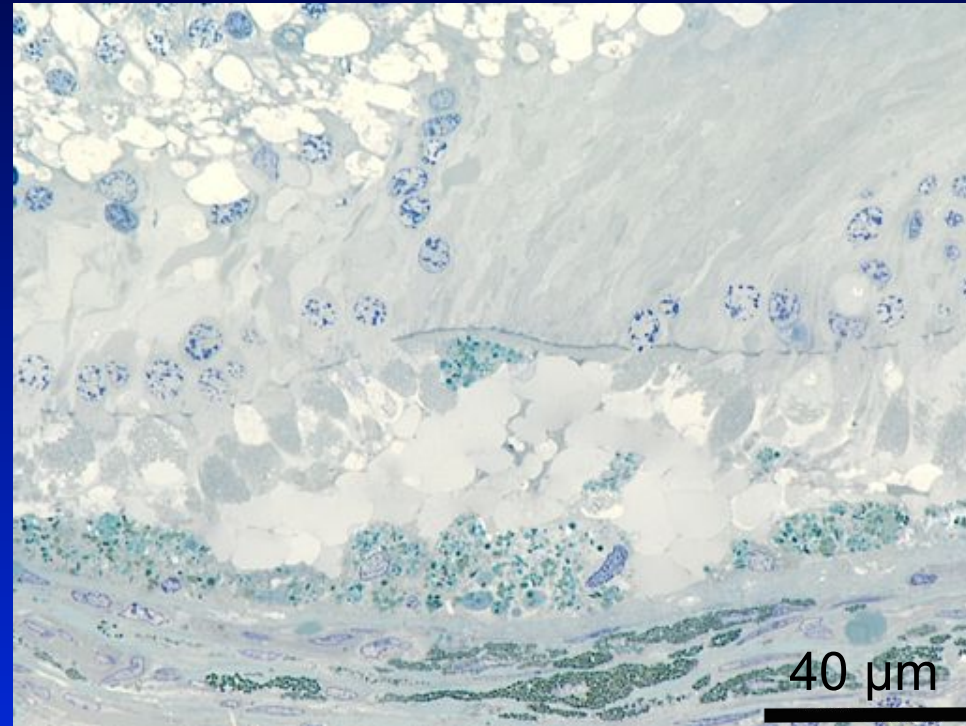
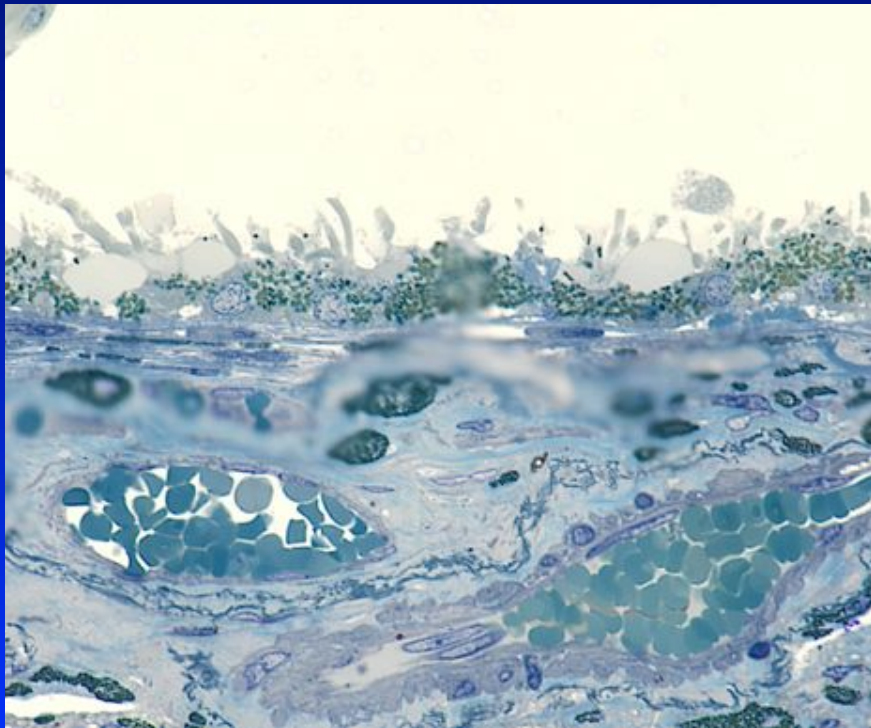
4

6

7

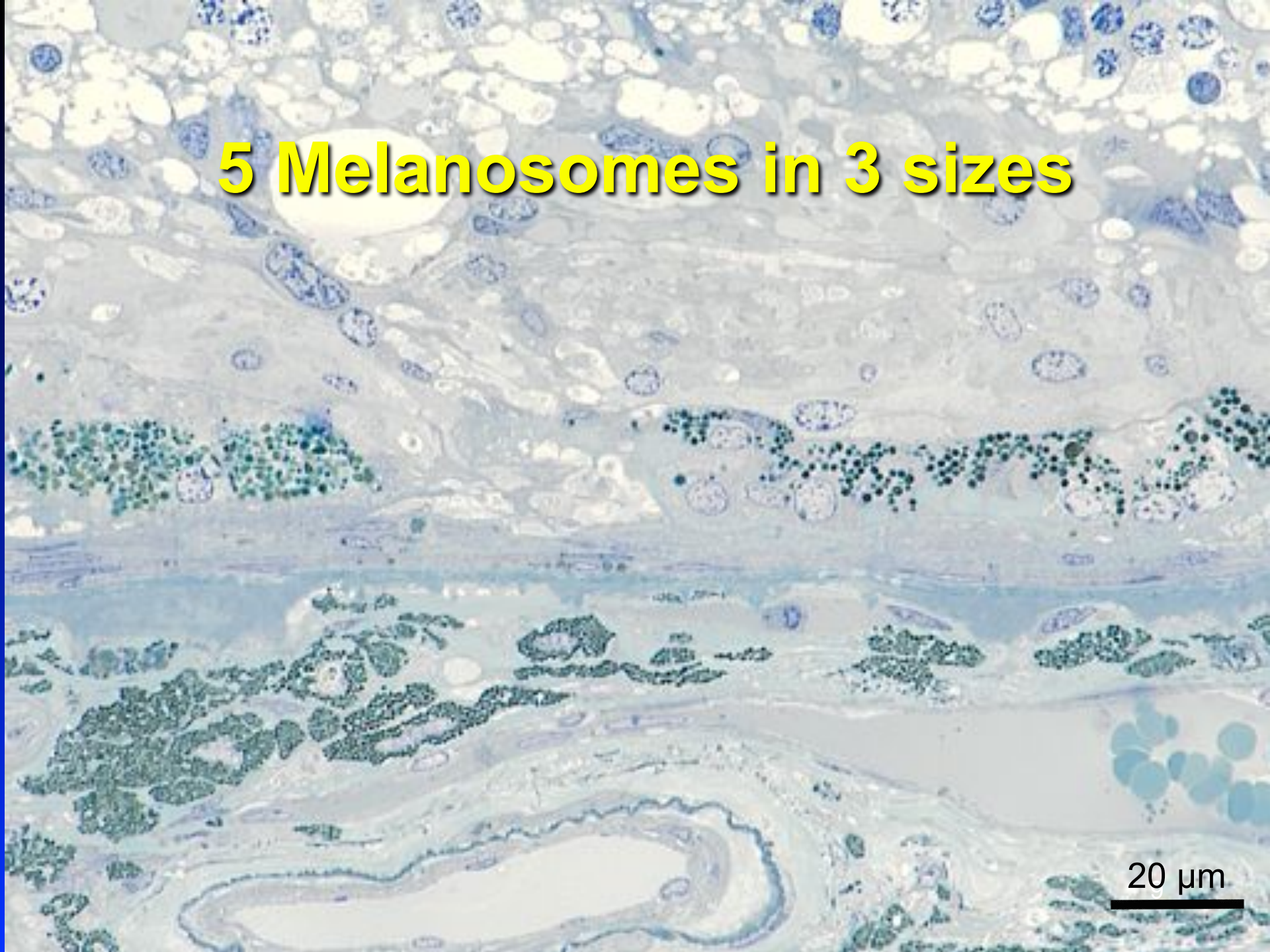
7

# 3 Subretinal lipid droplets; 4 new SDD?



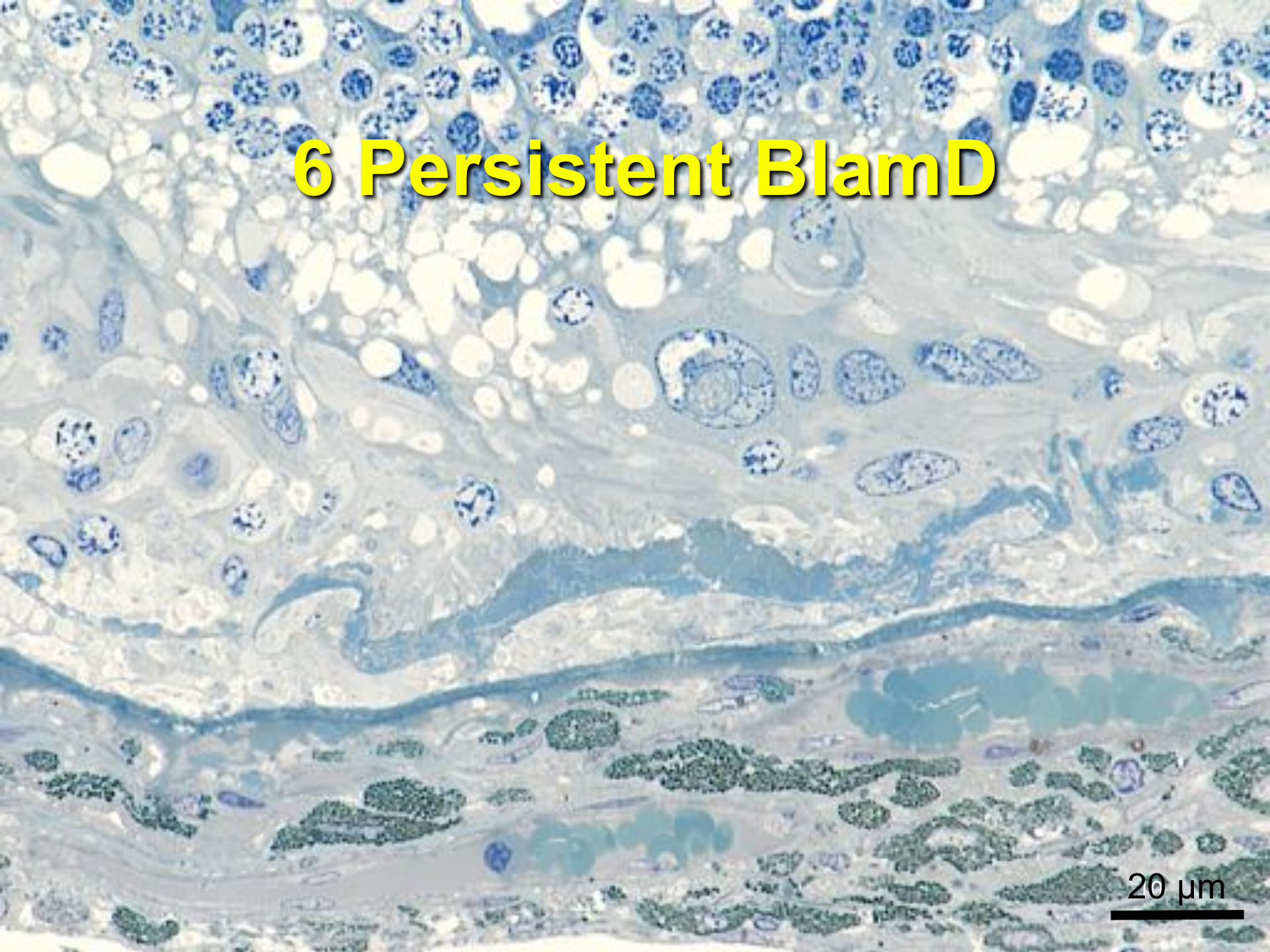


# 5 Melanosomes in 3 sizes



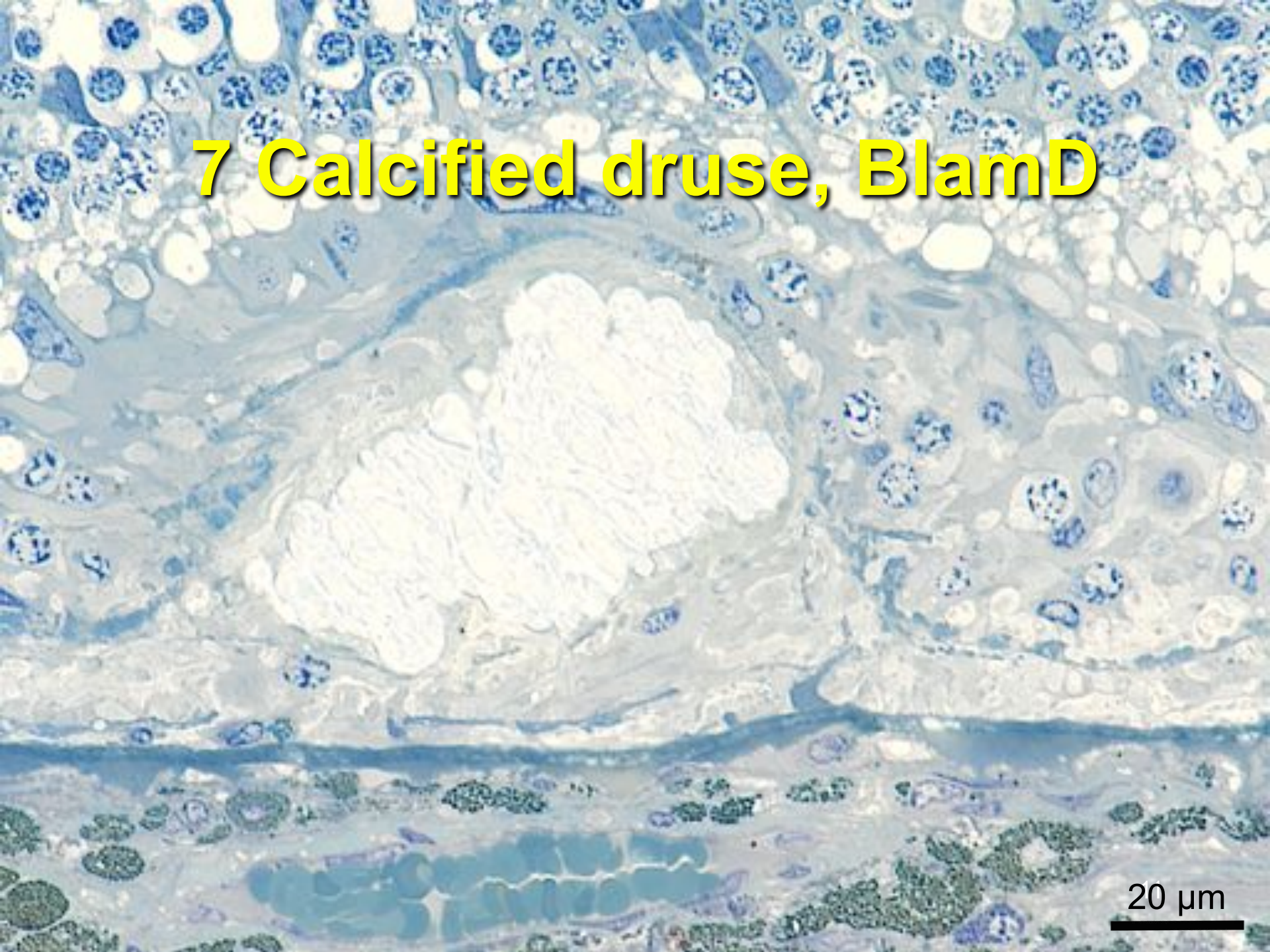20  $\mu\text{m}$

# 6 Persistent BlamD



20  $\mu$ m

# 7 Calcified druse, BlamD



20  $\mu$ m

# Project MACULA Case Report

Christine A. Curcio, PhD

