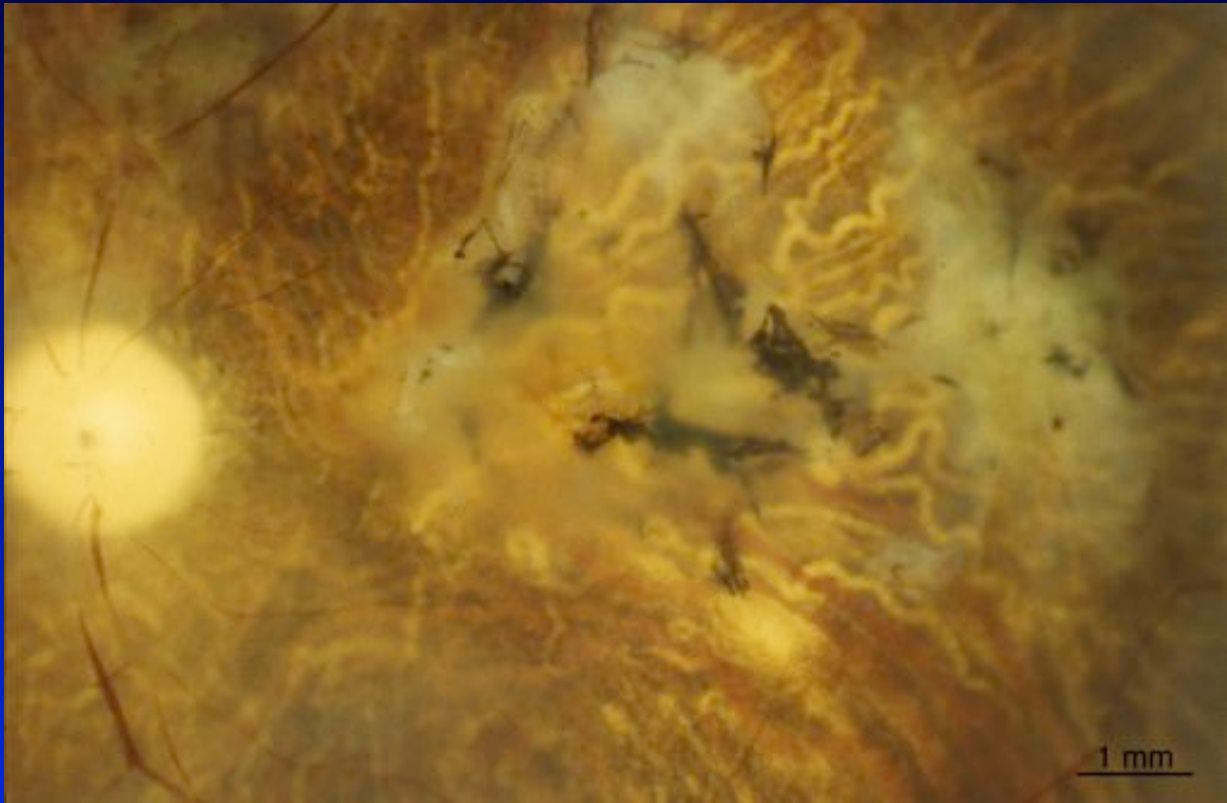



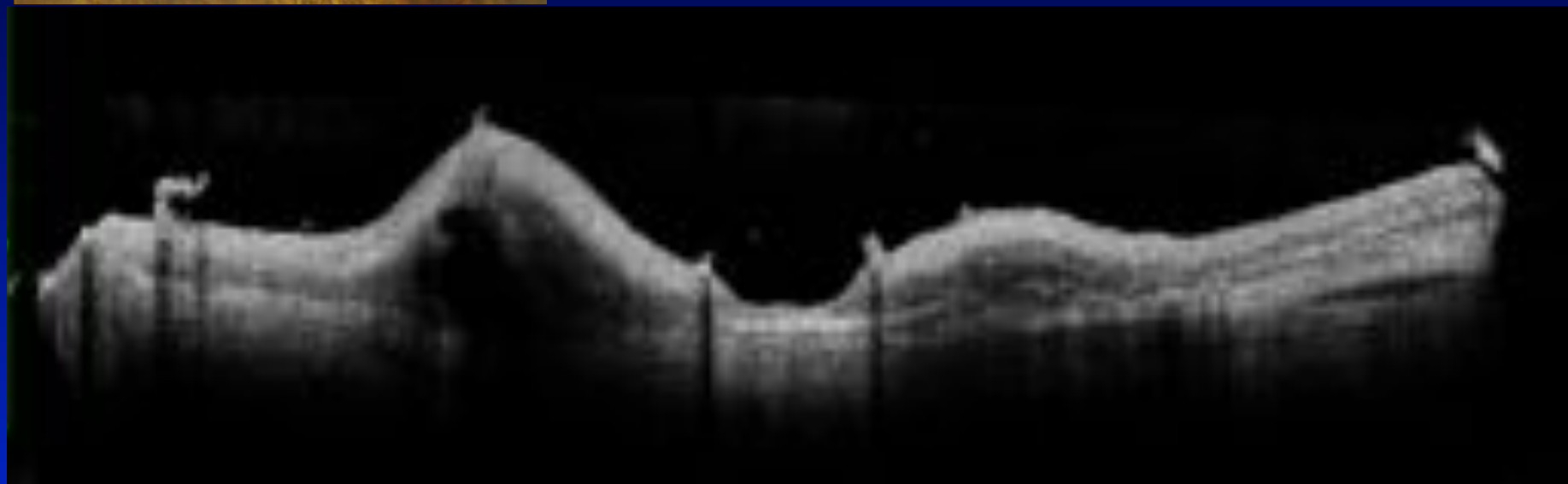
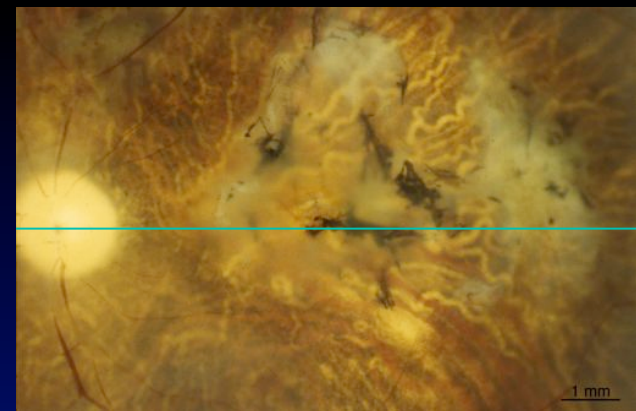
Project MACULA Case Report

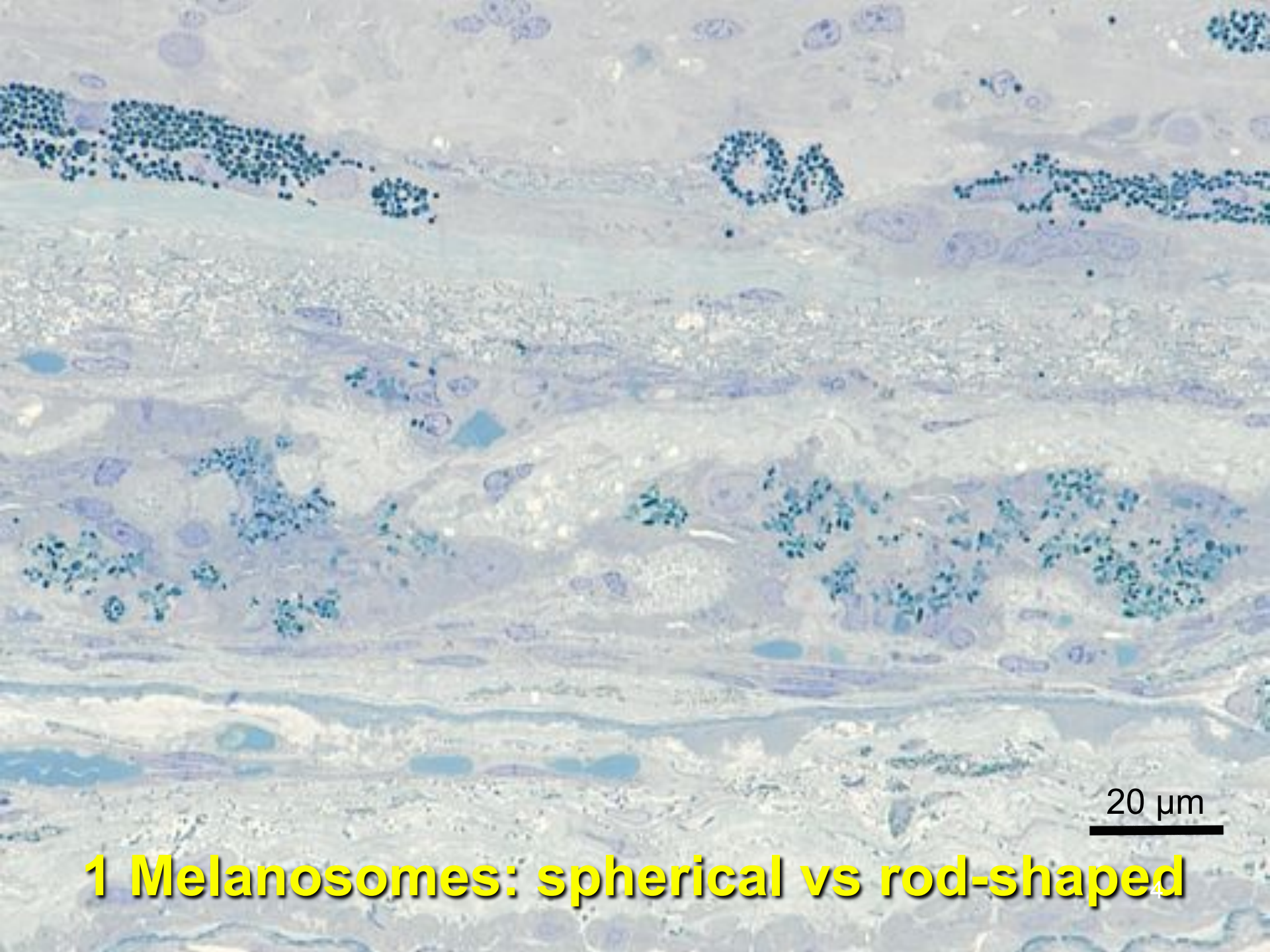
0096038L

84 yr old Caucasian male
Neovascular AMD



Foveal sections

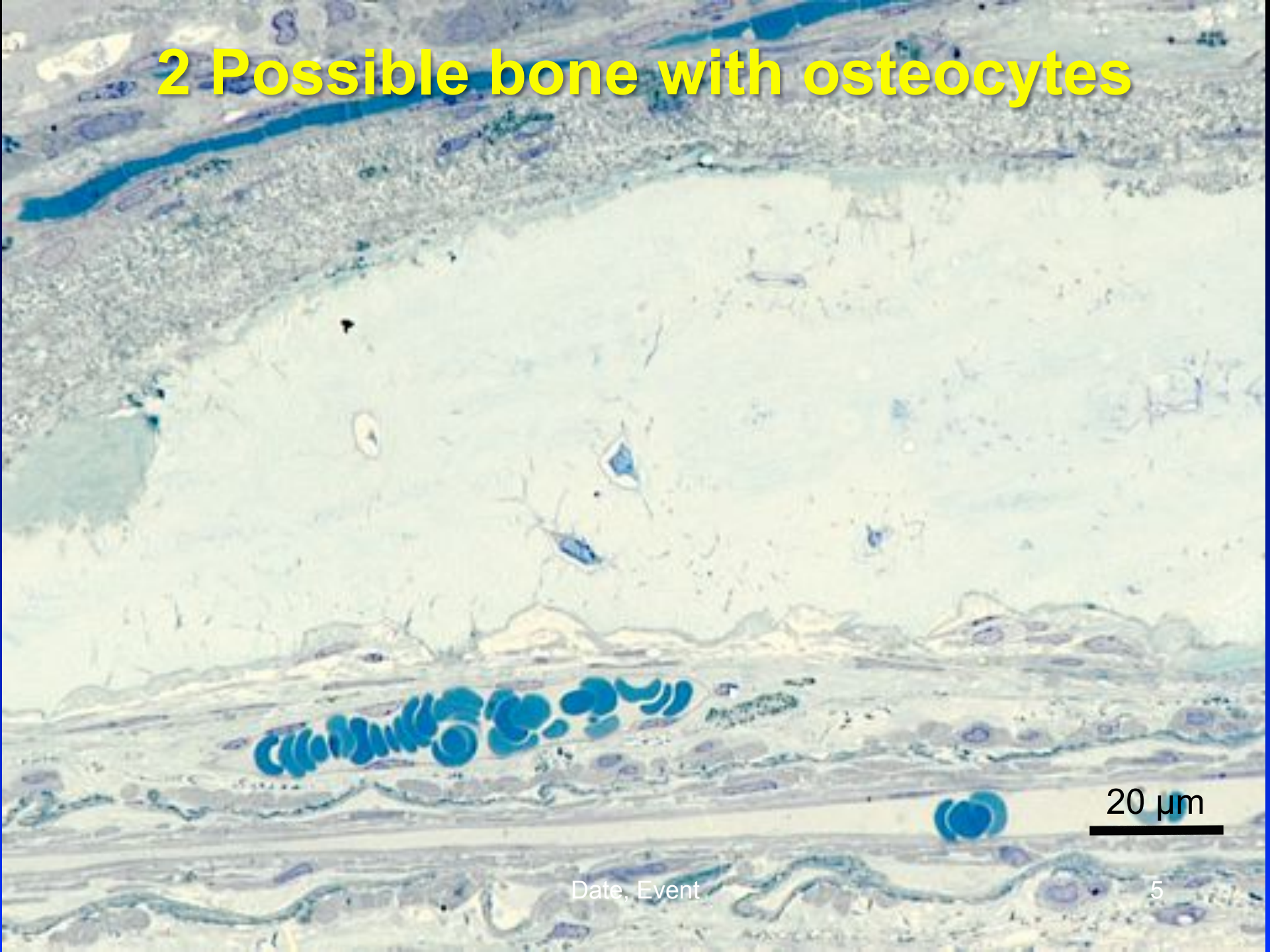




20 μm

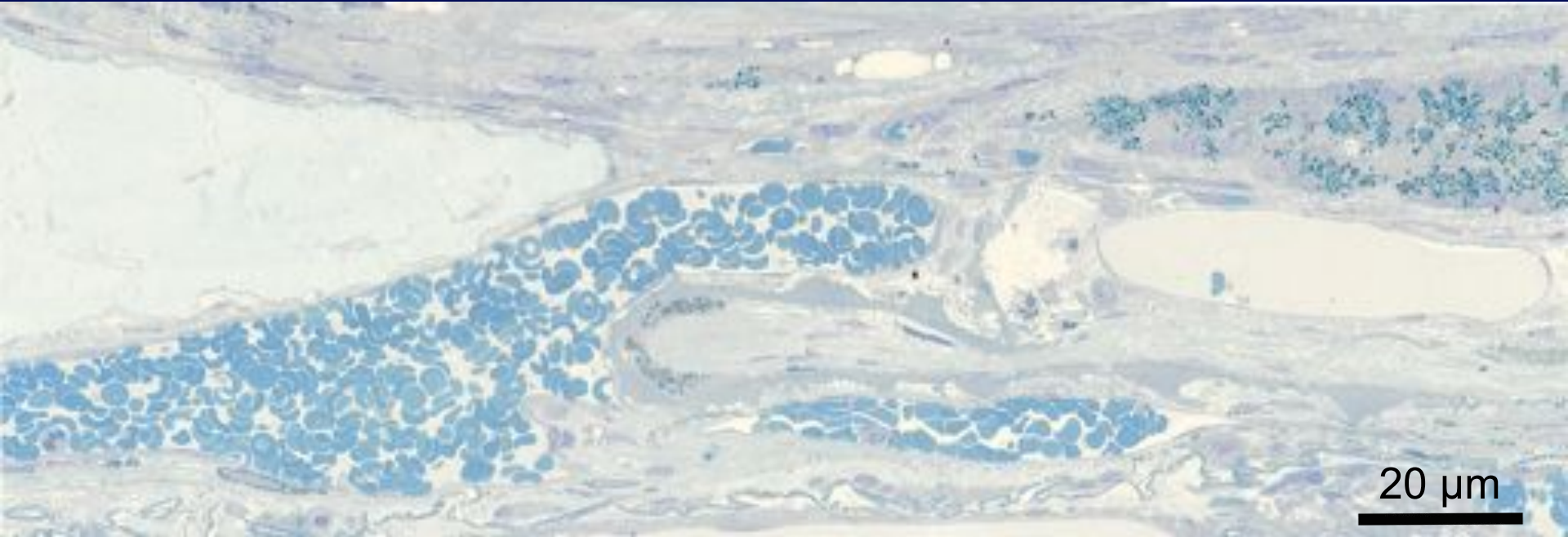
1 Melanosomes: spherical vs rod-shaped

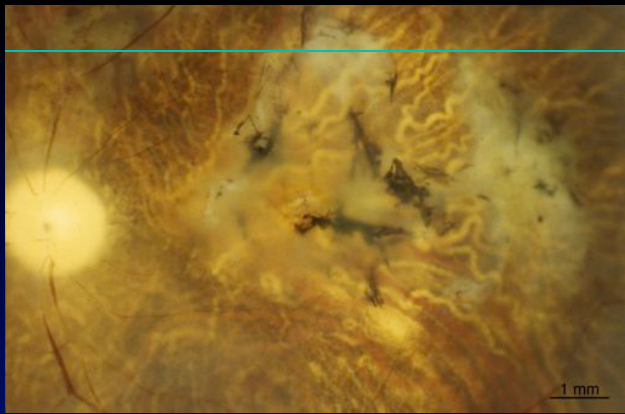
2 Possible bone with osteocytes




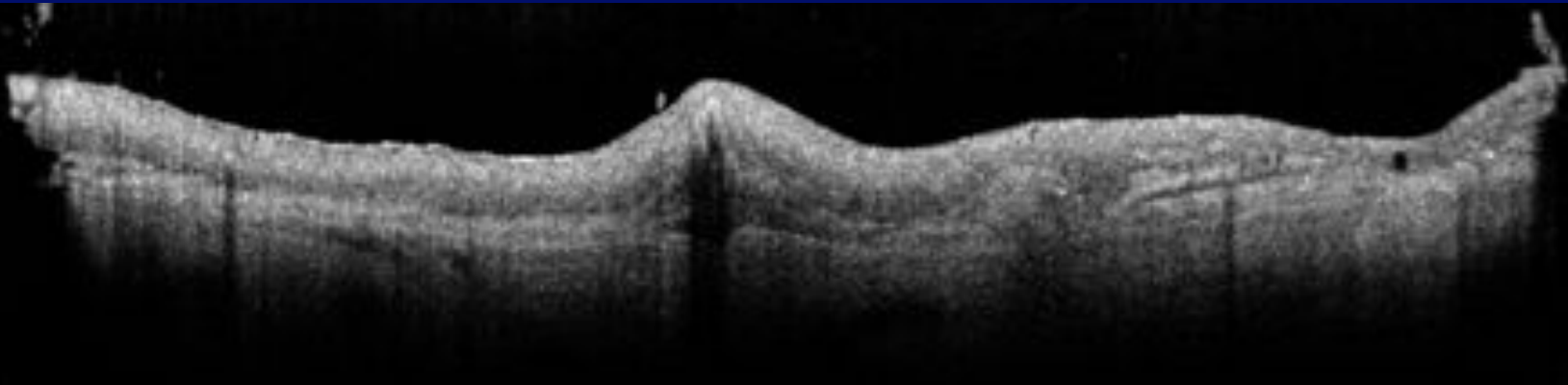
20 μ m

3 Reflected BrM with CNV





Perifoveal sections

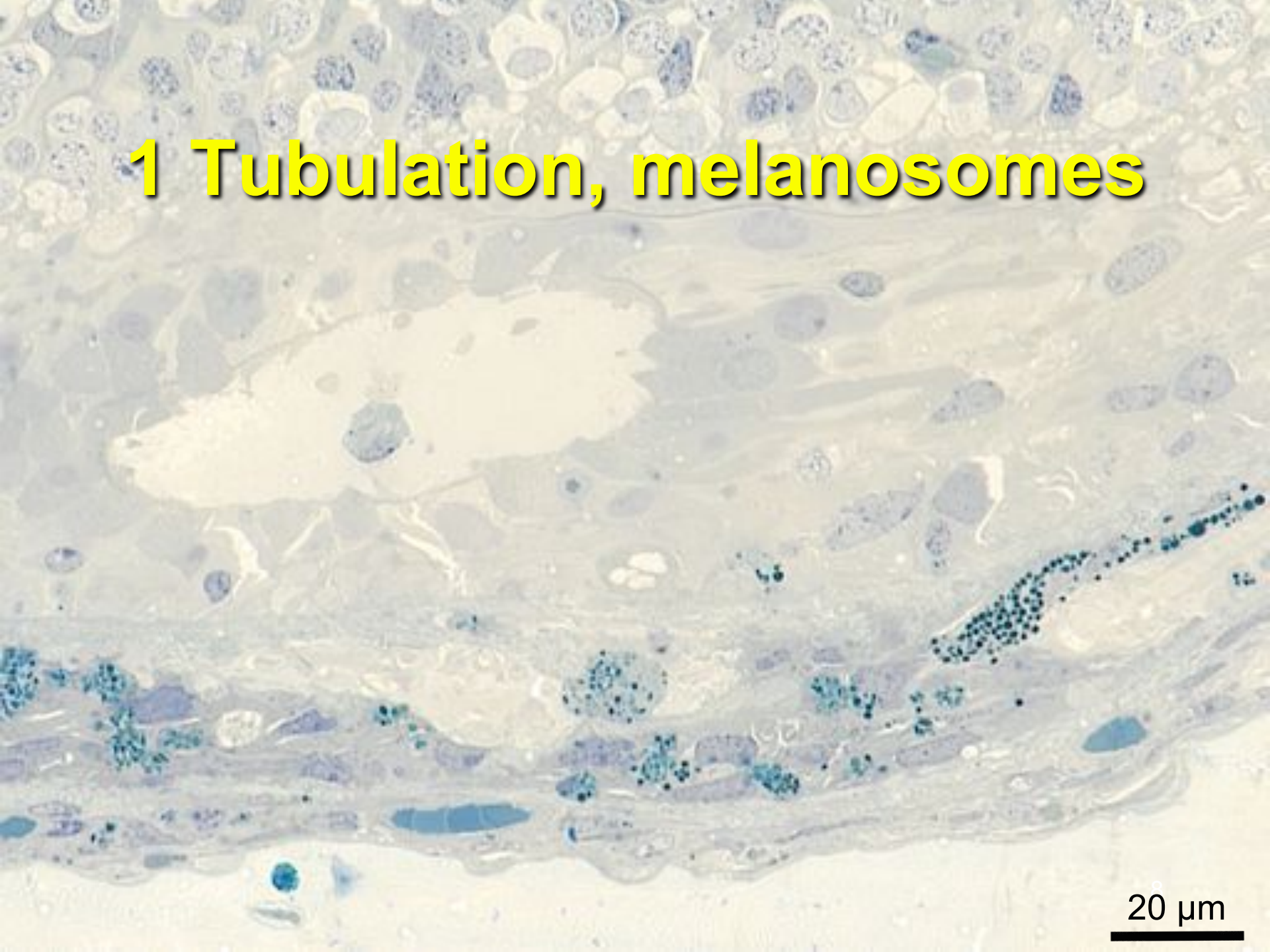


1

2

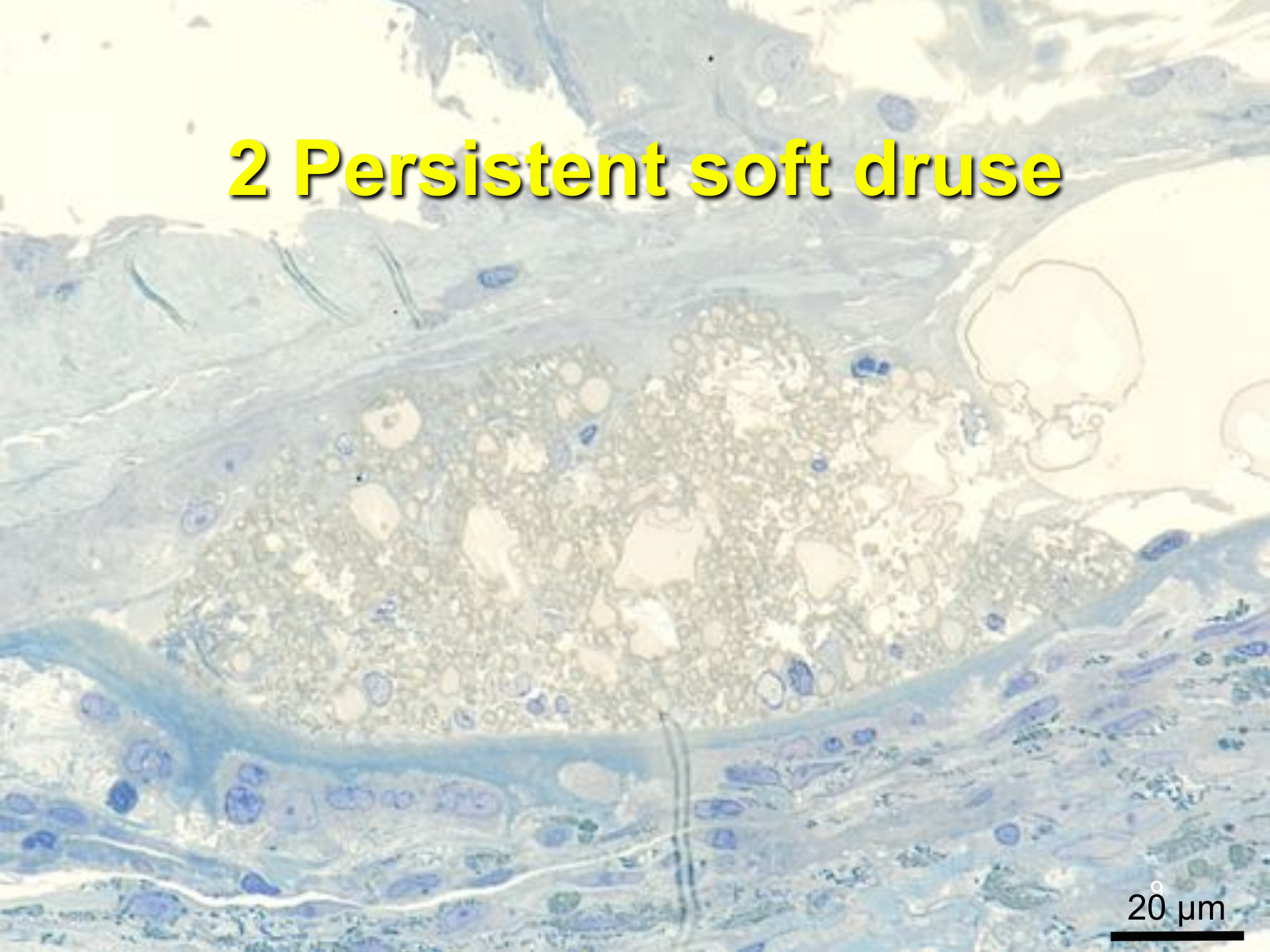7

1 Tubulation, melanosomes



20 μ m

2 Persistent soft druse



20 μm

Project MACULA Case Report

Christine A. Curcio, PhD

